

# The Importance of Iridocorneal Angle Anatomy in Clinical Decision Making

Automated gonioscopy with the GS-1 allows you to permanently record angle features, adding greater utility to an important examination technique in glaucoma patients and suspects.

BY CARLO E. TRAVERSO, MD



The usefulness of gonioscopy in patients with suspected or confirmed glaucoma is well established. While the most obvious reason to inspect the angle is to differentiate open- versus closed-angle, there are in fact several features of angle anatomy that help to optimize clinical management. One example is in an eye with an open, but narrow, angle that will likely require reevaluation in the future. In addition, findings suggesting pigment dispersion or exfoliation pose a greater risk for the onset of glaucoma, thus requiring monitoring. Moreover, closed-angle glaucoma actually describes a family of different glaucomas that are characterized by different features, and each may require different treatment approaches.

Several systems have been proposed for grading gonioscopic findings and classifying features of the iridocorneal angle (ICA) anatomy. In my view, the Spaeth Gonioscopic Grading System, first described in 1971,<sup>1</sup> offers the most complete assessment of anatomic features. This system includes a description of the true iris insertion in addition to the angular approach, the description of the profile of the peripheral iris, and characterization of trabecular meshwork pigmentation. The merits of the various grading systems for characterizing ICA anatomy have been debated for decades. My perspective is that using the Spaeth system involves a short learning curve, but the reason why it is so valuable is that it encourages the clinician to think beyond a binary characterization of the ICA as either open or closed; this is unique among the existing systems.

Ultimately, whether a grading system is used or not, it is important to identify the various features of the ICA anatomy and to direct decision-making accordingly.

## LIMITATIONS IN IMAGING THE ICA

Ideally, all patients being assessed for potential glaucoma would undergo a gonioscopic examination.<sup>2</sup> Unfortunately, studies suggest that up to 50% of glaucoma patients ever receive a gonioscopic examination.<sup>3,4</sup> Several factors are believed to be contributing to the underutilization of gonioscopy, including technical challenges in learning and

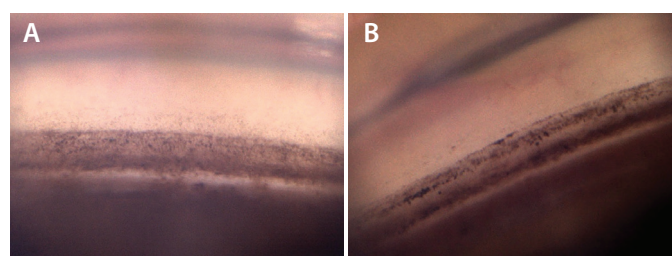
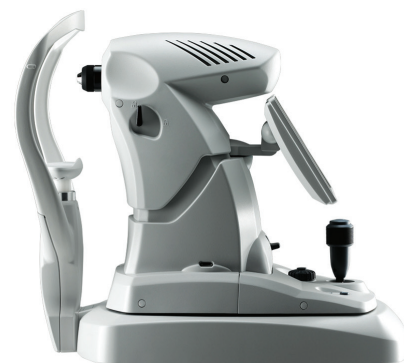

Figure 1. Single field image examples. Pigment dispersion syndrome (A) shows finely dispersed brownish pigment similar to cinnamon powder. In contrast, pseudoexfoliation (B) shows blackish more granular pigment, often peculiarly distributed on and beyond the Schwalbe's line forming the undulating Sampaolesi's line, specific to this condition.

performing the proper technique, lack of time, and patient discomfort. Additionally, overreliance on advanced imaging modalities may induce a decreased use of some of the essential steps in examining the eye, including performing direct ophthalmoscopy or gonioscopy.

Imaging is intended to complement the examination, adding to, but not replacing, the clinical assessment. This is because imaging platforms record measurements that are analyzed by software that builds images emulating the real anatomy. Imaging can be quite accurate and allows enhancement of selected details that might be of interest, but the images produced are not real. Viewing the anatomy and recording it photographically might not be the best or the most feasible technique for all eyes and all conditions, but the image is real. This is a subtle difference but one that can have relevant implications for making decisions.

During gonioscopy, the clinician views the anatomy, makes notes on the various anatomic features, and characterizes the features of the ICA. To take photographs during gonioscopy is obviously possible, but it is time-consuming and not simple. In this regard, the recent availability of an automated gonioscopy platform, the GS-1 Gonioscope (NIDEK), is an intriguing option that would be suitable for almost any style of practice and particularly for those who manage a high volume of glaucoma cases.

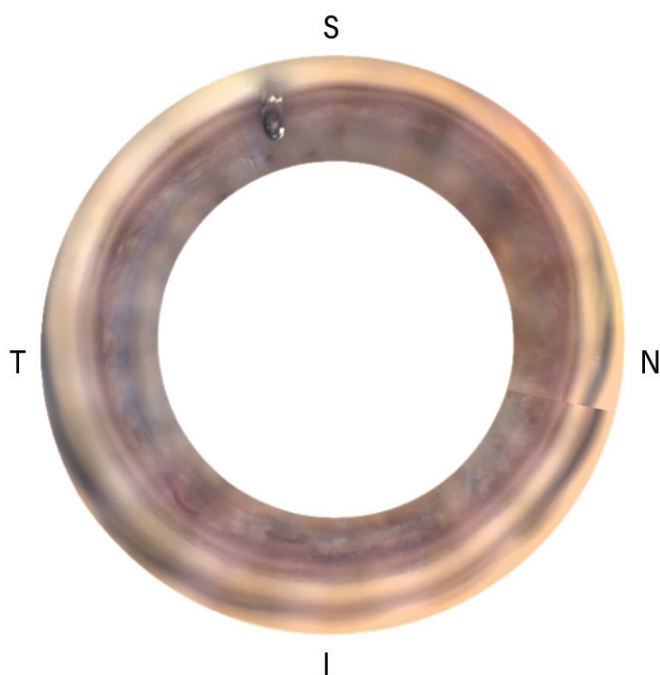


Figure 2. A circular stitching view of an EX-PRESS Glaucoma Filtration Device (Alcon).




Figure 3. A linear stitching view of an EX-PRESS Glaucoma Filtration Device.

### AUTOMATED GONIOSCOPY IN REAL-WORLD SETTINGS

One important feature of the GS-1 is that the images are taken and shown in color. This may become important, for example, when trying to distinguish between brownish pigmented deposits that suggest pigment dispersion syndrome and the blackish appearance of trabecular pigment in pseudo-exfoliation (Figure 1)—two entities that have different clinical behavior. These characteristics are typically observed with gonioscopy during the clinical examination and recorded in the patient's chart by hand. On the other side, attaching an actual photograph from the GS-1 is far simpler and much more definitive. Moreover, such distinctions could not be made using black-and-white gonioscopic photography.

In addition, the GS-1 captures a high-resolution image for up to 360° of the ICA. Similarly to popular imaging modalities, such as anterior chamber OCT, ultrasound biomicroscopy, and the Scheimpflug camera, the GS-1 may be operated by a technician, which is an advantage for workflow. A full-field image called “stitching” can be created by covering the 360° of the ICA on the circular and linear ways (Figures 2 and 3).

My impression is that the GS-1 should not completely replace examination with a goniolens. On the contrary, learning

the technique required to perform a correct gonioscopic examination and repeating it in different patients provides an opportunity to become familiar with the ICA anatomy. At the same time, it may be important to document the results with a photograph. There is a multitude of scenarios where this kind of photographic evidence could be relevant, including the comparison of serial images as patients are observed over time; documenting the angle in preparation for glaucoma surgery, especially when the placement of a stent is planned; and observing and documenting the angle after glaucoma surgery to confirm the position of any implanted device. In case of primary angle closure, early lens extraction with IOL placement has emerged as a viable treatment option in selected patients,<sup>5-7</sup> emphasizing the need for gonioscopic documentation. Besides the clinical use, goniophotography would help in case a medicolegal issue arises.

### CONCLUSIONS

The availability of automated gonioscopy changes how gonioscopy may be used in patients with suspected or confirmed glaucoma for the better. It basically takes less than 1 minute per eye examined, and it is possible for a technician to perform goniophotography, which is of benefit for the clinician, allowing more time for the clinician to focus on tasks that require the expert input of the ophthalmologist.

In short, the GS-1 is an instrument able to improve the efficiency of gonioscopy, which is sometimes considered a time-limiting procedure. Since all the features are visible and recordable, the GS-1 photographs are usable with the Spaeth system to grade and classify the anatomy. In addition, because the photograph obtained is an actual representation and not a reconstructed image, it can be used for detailed recording of the ICA anatomy and allows for accurate follow-up. ■

1. Spaeth GL. The normal development of the human anterior chamber angle: a new system of descriptive grading. *Trans Ophthalmol Soc UK*. 1971;91:709-739.
2. Prum BE Jr, Herndon LW Jr, Moroi SE, et al. Primary angle closure preferred practice pattern guidelines. *Ophthalmology*. 2016;123(11):P1-P40.
3. Coleman AL1 Yu F, Evans SJ. Use of gonioscopy in medicare beneficiaries before glaucoma surgery. *J Glaucoma*. 2006;15(6):486-493.
4. Varma DK, Simpson SM, Rai AS, Ahmed IK. Undetected angle closure in patients with a diagnosis of open-angle glaucoma. *Can J Ophthalmol*. 2017;52(4):373-378.
5. Azuara-Blanco A, Burr J, Ramsay C, et al; EAGLE study group. Effectiveness of early lens extraction for the treatment of primary angle-closure glaucoma (EAGLE): a randomised controlled trial. *Lancet*. 2016;388(10052):1389-1397.
6. Traverso CE. Clear-lens extraction as a treatment for primary angle closure. *Lancet*. 2016;388(10052):1352-1354.
7. Traverso CE, Cutolo CA. The effects of phacoemulsification and intraocular lens implantation on anatomical and functional parameters in patients with primary angle closure: a prospective study. *Trans Am Ophthalmol Soc*. 2017;115:17.

### Carlo E. Traverso, MD

- Professor and Chairman, Clinica Oculistica Universitaria, Department of Neurosciences, Ophthalmology and Genetics, Ospedale Policlinico San Martino—IRCCS, Genova, Italy
- Financial disclosure: Research Support (NIDEK); Travel Compensation (NIDEK)