

# The Advantages of Optical Coherence Tomography (OCT) for Early Diagnosis of Glaucoma



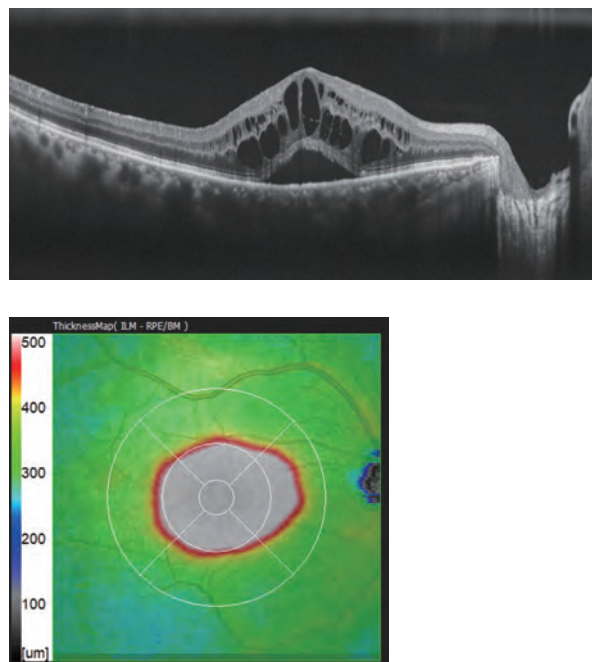
**By Alejandro Villalobos, MD**

Exilaser Clinic, Lima, Peru

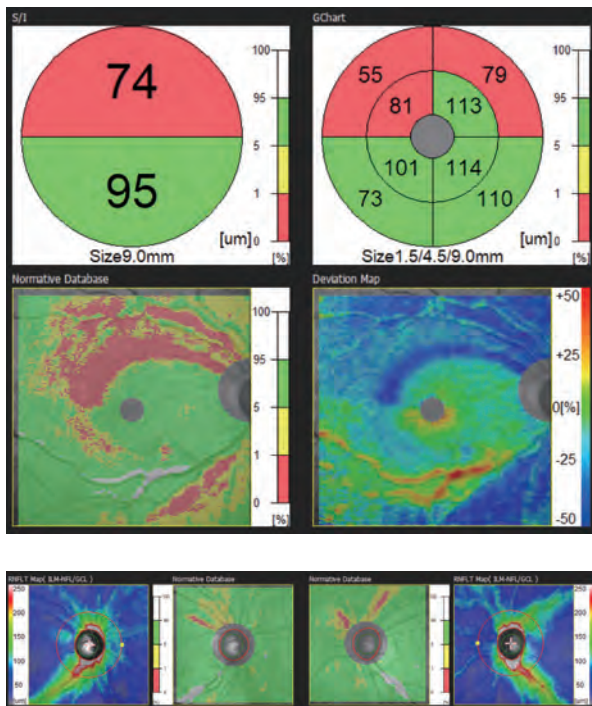
Historically, the diagnosis of (open angle) glaucoma is based on three diagnostic pillars: changes in the optic nerve, loss of visual field and elevated intraocular pressure <sup>(1)</sup>. However, this paradigm has gradually changed with the continuous advances in technology and the development of various diagnostic tools, and multiple therapeutic options both in the pharmacological and surgical fields. While these three pillars remain a fundamental aspect of the diagnosis, early detection of glaucoma is clinically challenging. There is evidence that OCT imaging can aid in diagnosing pre-perimetric glaucoma <sup>(2-4)</sup>. Early detection allows early onset of therapy, reducing the rate of progression. However, early diagnosis of glaucoma remains clinically challenging, because the characteristics evaluated are more subtle and may be common to other pathologies such as compression of the optic chiasm, a tilted optic disc and high myopia <sup>(5, 6)</sup>. This is especially the case for the structural evaluation of the optic nerve <sup>(5, 6)</sup>.

The current OCT devices acquire images of the retina and the optic disc in exquisite detail, generating large volumes of data (a single scan easily occupies 32 MB). These translate into a significant amount of information that must be presented in a manner that improves clinical interpretation; otherwise, superfluous information is presented that can be confusing. Unlike macular diseases, the

diagnosis of glaucoma is mainly based on the analysis of the quantitative representation performed by the device (**Figure 1**). The latter differs markedly between brands and depends on the software inherent to the specific device. It is here that the RS-3000 Advance 2 / NAVIS-EX platform clearly demonstrates a clinical approach, without neglecting statistical details yet minimizing an “engineering” layout that sometimes makes the study clinically ambiguous.



**Figure 1** Cystoid macular edema. Above: Sectional image of intraretinal hyporeflective cysts and central neuroretinal detachment. Below: Macular thickness map indicating a homogeneous central elevation.



**Figure 2** Glaucoma. Above: 9 × 9 mm macula map with an asymmetric defect respecting the temporal horizontal midline. Below: 6 × 6 mm optic disc map with multiple peripapillary defects.

## 1. Comprehensive evaluation of ganglion cells at the macular level

Unlike other OCT devices, the RS-3000 Advance 2 allows comprehensive evaluation of the ganglion cells, within a 9 × 9 mm area (in an emmetropic eye) to easily visualize the typical asymmetric altitudinal/arcuate defects that characterize glaucoma. These characteristic patterns can be visualized in different ways: the normative map allows an intuitive interpretation, while the deviation map provides more details on a continuous color scale. Additionally, quantitative evaluation and direct comparison of asymmetry can be performed between quadrants <sup>(5)</sup> (**Figure 2**). An additional useful feature is the simultaneous visualization of full retinal thickness, which helps rule out pathologies that affect other retinal layers.

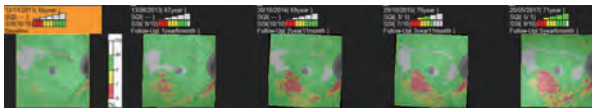
Lastly, the *en-face* projection allows an evaluation of the inner retinal surface for membranes or other pathology that may affect thickness measurements.

## 2. Quantitative map of the peripapillary retinal nerve fiber layer with optic disc topography

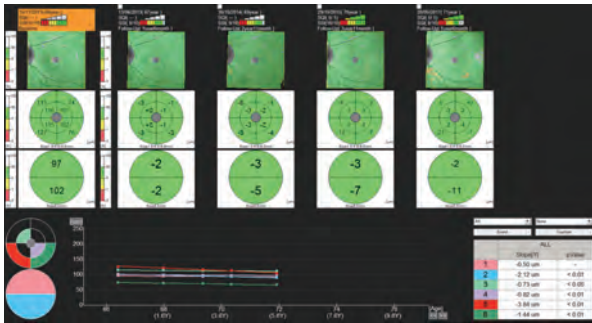
In patients with glaucoma, the 6 × 6 mm map centered on the optic nerve shows the typical radiating defects of the retinal nerve fiber layer (RNFL). The cSLO (confocal scanning laser ophthalmoscope) provides high contrast, clear images of the neuroretinal rim and the possible notches, as well as regions of peripapillary atrophy and vascular anatomical variants of the retina. The topographic information (which can be adjusted with the interactive editor), the peripapillary thickness and the OD/OS symmetry, complement the evaluation of this map.

## 3. Qualitative evaluation of peripapillary RNFL with a circumpapillary scan

In particular, I consider the peripapillary circular scan (3.45 mm) very useful not only quantitatively but qualitatively, allowing detailed evaluation of the images where, often, we find small hyporeflective spaces adjacent to vascular structures, such as the prominence of the latter over the RNFL, signs associated with glaucoma <sup>(7)</sup>.



**Figure 3a** Five-year follow-up of glaucomatous progression showing the development of an inferior arcuate defect.



**Figure 3b** Five-year follow-up showing no color change on the normative map. However, the numerical values indicate a clear statistically significant progression in the selected sectors.

## 4. Comparative monitoring of changes in the thickness of ganglion cells

Regardless of the technology used for the diagnosis of glaucoma, follow-up examination is considered an essential tool for diagnosis and progression of disease <sup>(4)</sup>. The RS-3000 Advance 2 / NAVIS-EX platform clearly and graphically shows how a glaucomatous defect evolves asymmetrically (**Figure 3a**). It also plots thickness of the selected quadrants over time for assessing whether the annual rate of loss is statistically significant so that very subtle changes can be detected even before they appear on the normative map (**Figure 3b**). An additional advantage of reviewing the macular region is the lower anatomical variability compared to the peripapillary area, which sometimes is extremely difficult to assess, like in high myopia.

## The three structural pillars for diagnosing glaucoma

It is important to recognize that, although the OCT is an ancillary study, we can use the same three-pillar strategy to give it greater clinical significance, seeking congruence between: the radiating peripapillary defects (in the optic nerve map), microstructural changes (at the peripapillary level in the high resolution image of the circular scan) and the asymmetric ganglion cell defects at the macular level.

## The future


OCT angiography is the latest step in the continuous evolution of this technology <sup>(8)</sup>. This modality allows the visualization of microvascular details in the macula and optic nerve, as well as “quantification” of blood flow through density and vascular perfusion maps <sup>(7)</sup>. There is scientific evidence of vascular changes associated with glaucoma <sup>(9, 10)</sup>. However, the fact that vascular blood flow can be affected by numerous conditions and physiologic variation <sup>(9)</sup>, implies a very cautious evaluation and assessment, perhaps beyond what the current clinical application allows. This field is ideal for the application of new technologies such as convolutional neural networks and other forms of artificial intelligence for the recognition and classification of images.

## References

1. Stamper RL, Lieberman MF, Drake MV, Becker B. Becker-Shaffer's Diagnosis and Therapy of the Glaucomas. Elsevier Health Sciences; 2009. 581 p.
2. Sung KR, Na JH, Lee Y. Glaucoma diagnostic capabilities of optic nerve head parameters as determined by Cirrus HD optical coherence tomography. J Glaucoma 2012;21:498–504.
3. Lisboa R, Paranhos A, Jr, Weinreb RN, et al. Comparison of different spectral domain OCT scanning protocols for diagnosing preperimetric glaucoma. Invest Ophthalmol Vis Sci 2013;54:3417–25.
4. Cennamo G, Montorio D, Velotti N, Sparnelli F, Reibaldi M, Cennamo G. Optical coherence tomography angiography in pre-perimetric open-angle glaucoma. Graefes Arch Clin Exp Ophthalmol. 2017;255(9):1787-1793.
5. Bussell II, Wollstein G, Schuman JS. OCT for glaucoma diagnosis, screening and detection of glaucoma progression. Br J Ophthalmol. 2014 Jul;98 Suppl 2:ii15-9.
6. Brusini P. OCT Glaucoma Staging System: a new method for retinal nerve fiber layer damage classification using spectral-domain OCT. Eye (Lond). 2018;32(1):113–9.
7. Ou Tan, Shandiz Tehrani, Brandon V Orozco, Xiaogang Wang, Yali Jia, Martin F Kraus, James G Fujimoto, David Huang; Pilot Study of Optical Coherence Tomography Measurements of Retinal Vessel Relief Height in the Detection of Glaucoma. Invest. Ophthalmol Vis. Sci. 2014; 55 (13): 951.
8. Yilmaz H, Karakurt Y, Icel E, Ugurlu A, Ucak T, Tasli NG, Elpeze SB. Normative Data Assessment of Vessel Density and Foveal Avascular Zone Metrics Using AngioScan Software. Curr Eye Res. 2019 Dec;44(12):1345-1352.
9. Park HL, Kim JW, Park CK. Choroidal Microvasculature Dropout Is Associated with Progressive Retinal Nerve Fiber Layer Thinning in Glaucoma with Disc Hemorrhage. Ophthalmology. 2018 Jul;125(7):1003-1013.
10. Bojikian KD, Nobrega P, Wen JC, Zhang Q, Mudumbai RC, Johnstone MA, Wang RK, Chen PP. Macular Vascular Microcirculation in Eyes With Open-angle Glaucoma Using Different Visual Field Severity Classification Systems. J Glaucoma. 2019 Sep;28(9):790-796.

## Related product



Optical Coherence Tomography  
RS-3000 Advance 2 

(Model name: RS-3000 Advance)



### More clinical information available online at the NIDEK Education page

For more clinical information, please visit the Education page on the NIDEK website. This site allows access to case reports, journal articles, and video presentations.

<https://www.nidek-intl.com/education/>

