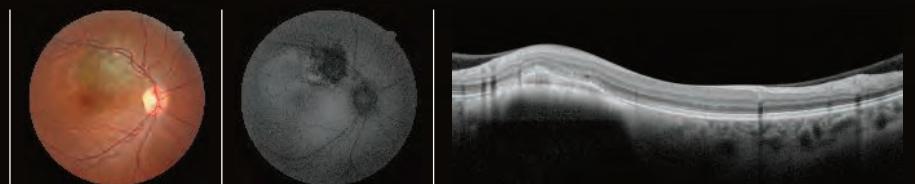




Fundus
AutoFluorescence Atlas
with the Retina Scan Duo Series



Giovanni Staurenghi, MD
Marco Pellegrini, MD
Mariano Cozzi, MSc

CONTENTS

INTRODUCTION	4
--------------	---

GEOGRAPHIC ATROPHY	6
--------------------	---

STARGARDT'S DISEASE	8
---------------------	---

RETINITIS PIGMENTOSA	10
----------------------	----

ANGIOID STREAKS	12
-----------------	----

CHOROIDAL MELANOMA	14
--------------------	----

LAMELLAR MACULAR HOLE	15
-----------------------	----

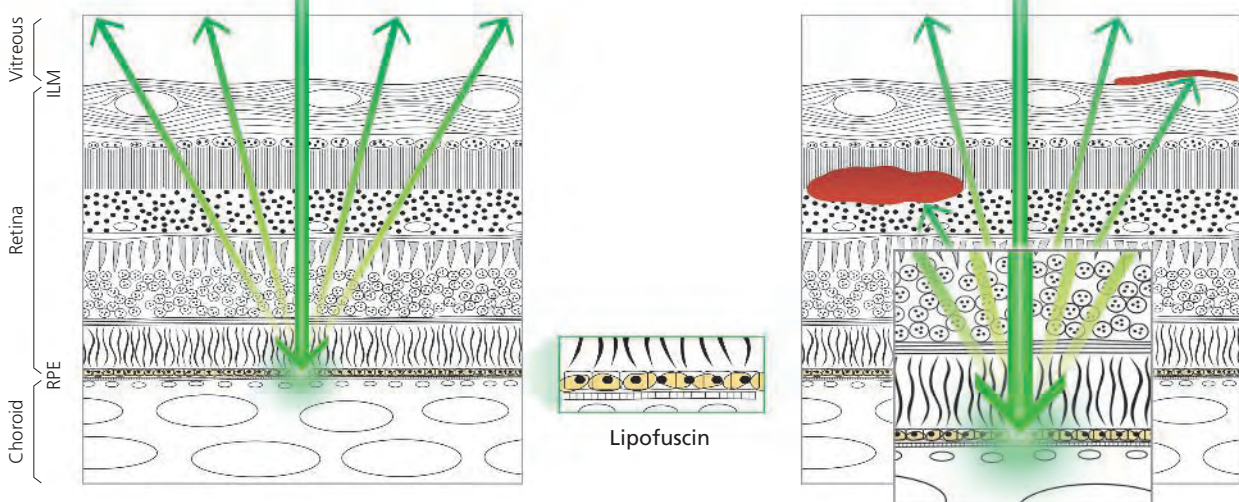
CONE DYSTROPHY	16
----------------	----

CENTRAL SEROUS CHORIORETINOPATHY	17
----------------------------------	----

INTRODUCTION

Fundus autofluorescence (FAF) is naturally emitted due to the presence of a substance called Lipofuscin in the RPE cells. When stimulated with a specific wavelength of light, Lipofuscin becomes fluorescent and its distribution can be mapped.

Hyper-fluorescence and hypo-fluorescence occur due to changes in the distribution of Lipofuscin caused by various pathologies. These changes in FAF allow the physician to interpret the effect of disease.



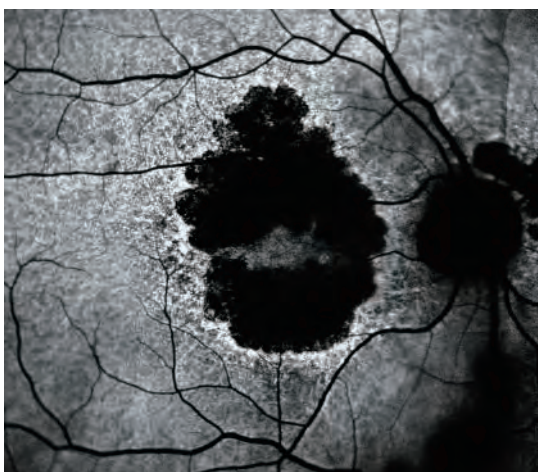


There are 2 types of autofluorescence depending on the wavelength of light stimulation: blue and green.

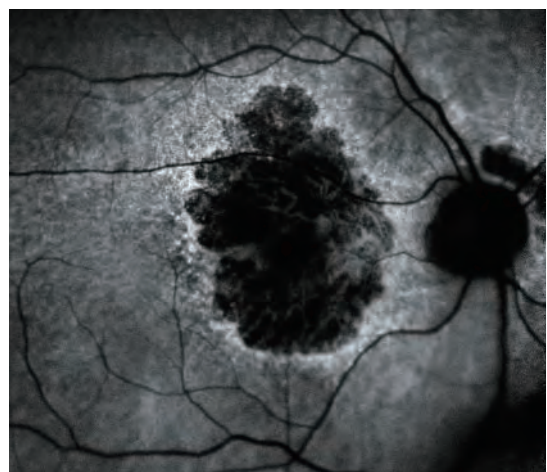
Blue light is normally absorbed by the macular pigment naturally present in the fovea, resulting in a darker spot compared to the central macula even in normal patients.

Green light is not absorbed resulting in images with no central hypo-fluorescent spot in normal macula.

Blue-FAF

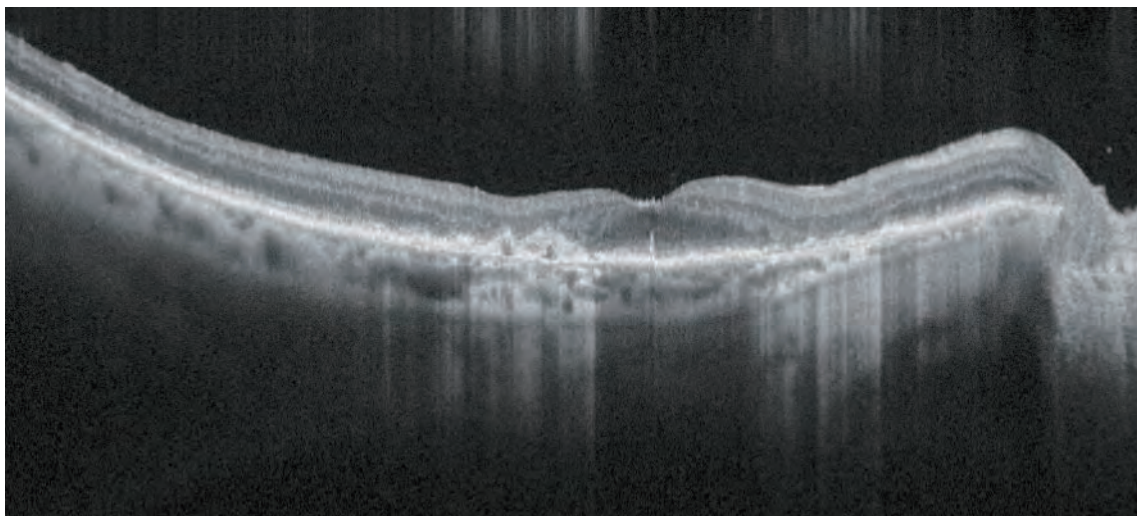
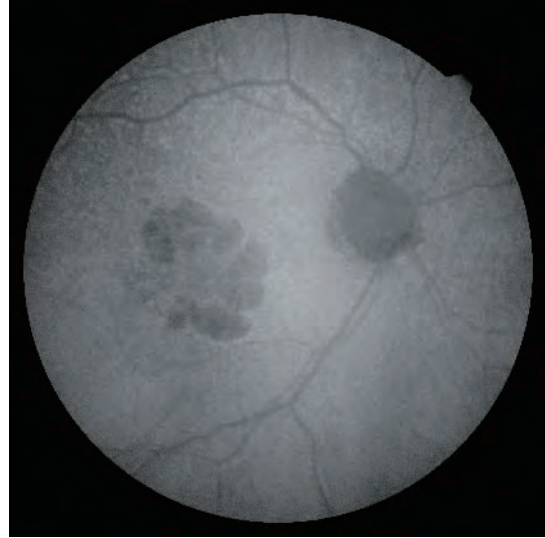
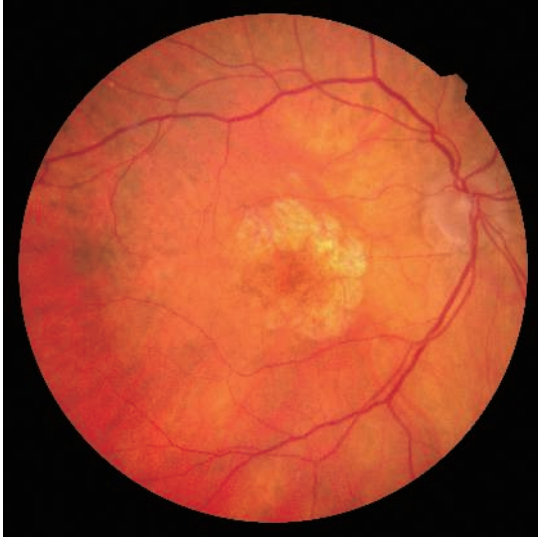

Green-FAF



Both images acquired with the Mirante Scanning Laser Ophthalmoscope

GEOGRAPHIC ATROPHY

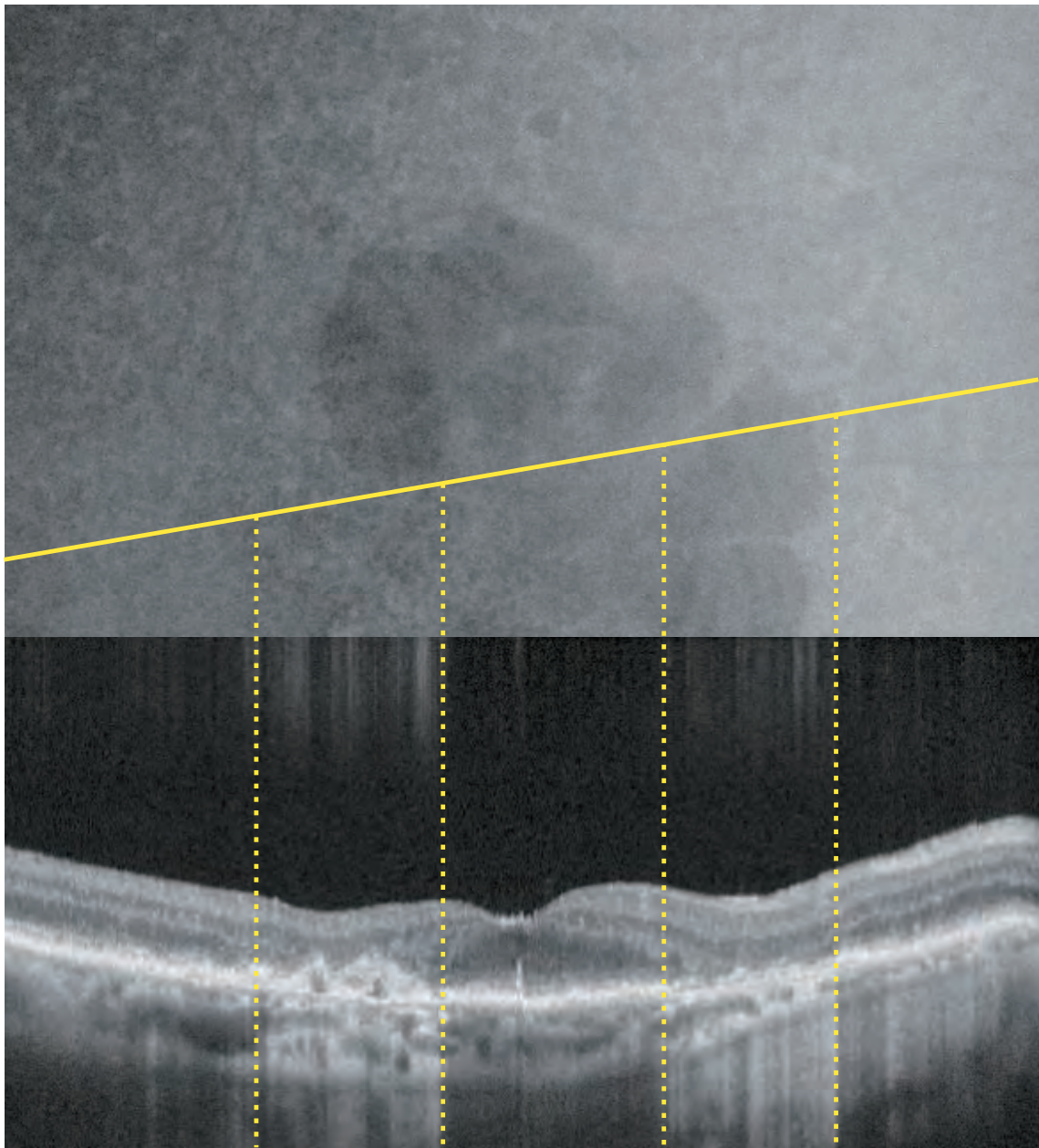


Macular Atrophy secondary to Age-related Macular Degeneration is also known as "**Geographic Atrophy**".

GA is a major cause of visual loss in the elderly, and foveal involvement occurs at end stage disease.

Fundus autofluorescence (FAF) is considered the optimal imaging modality to evaluate the extent of the atrophic area.

All clinical trials evaluating new treatments for GA include FAF as a primary tool for detection and analysis.

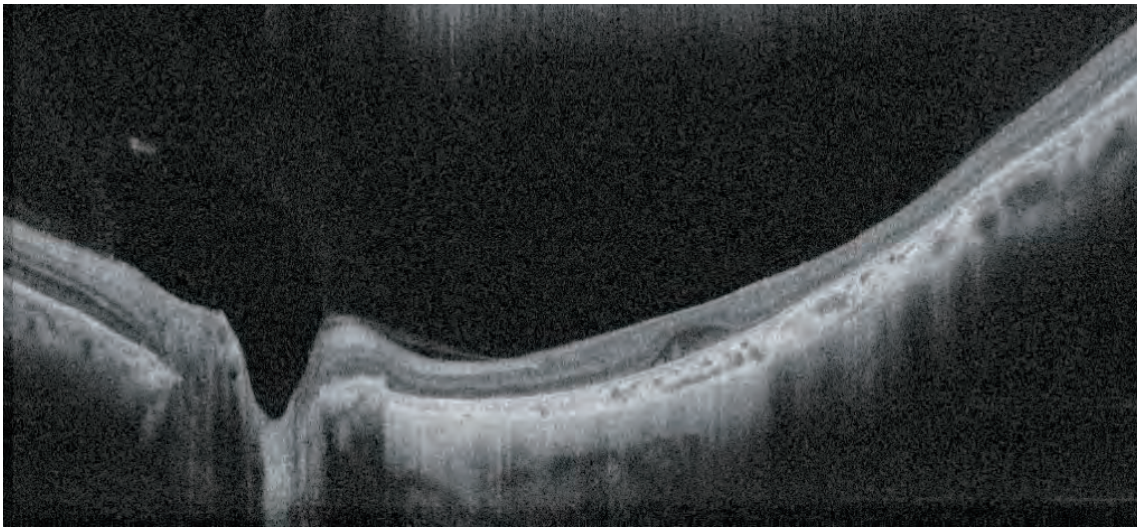
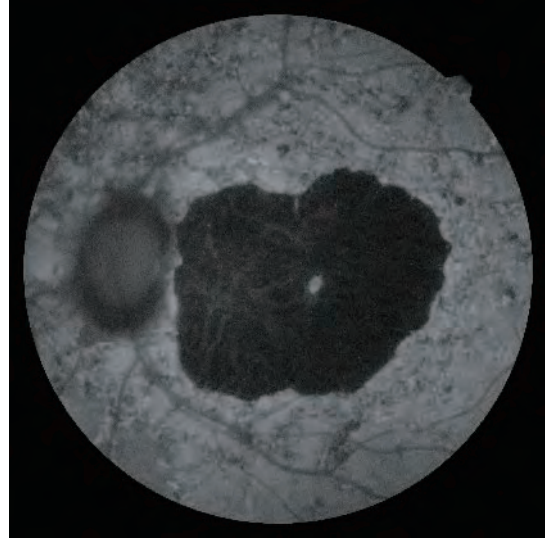
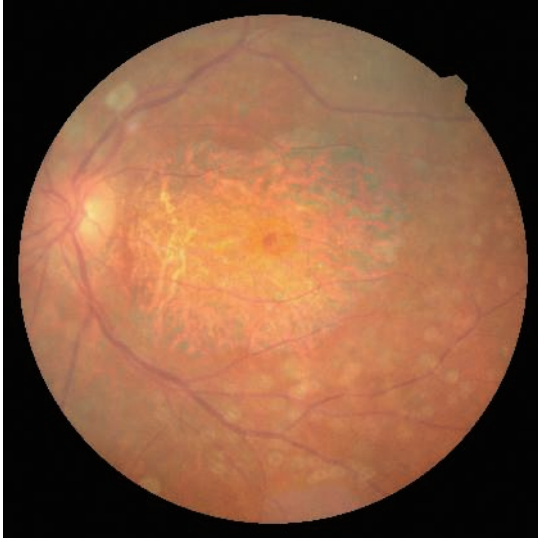


FAF shows dark “**hypo-fluorescent**” areas corresponding to the area of atrophy due to the loss of lipofuscin in the **RPE**.

Notably, the darkest spots in the FAF image correspond perfectly to **hyper-transmission** of light in the OCT B-scan image.

The advanced atrophy in this case reduces the high reflectivity that normally characterizes the **RPE** and allows the transmission of light to the choroid in this case.

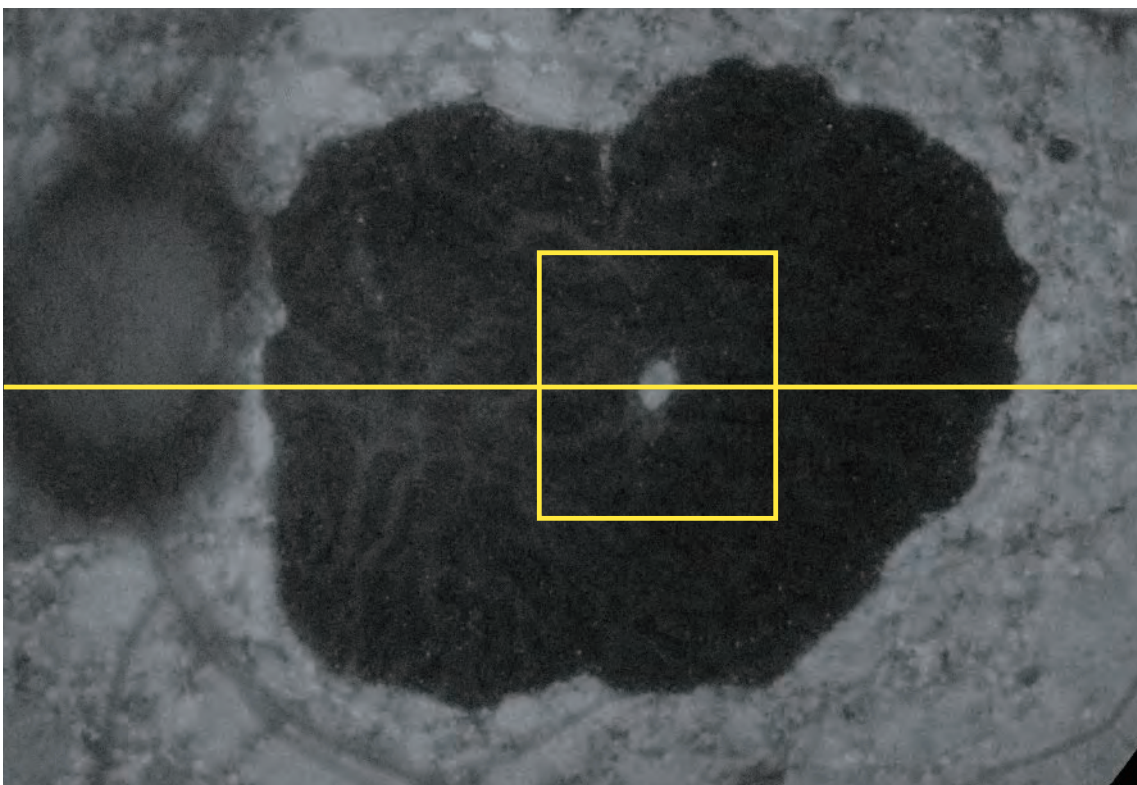
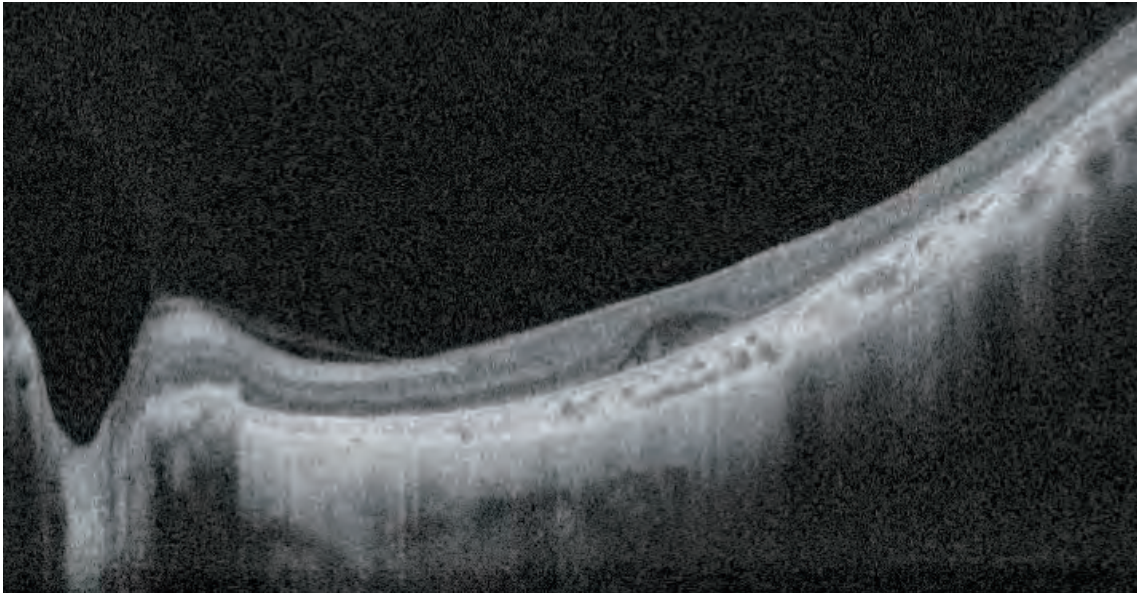
STARGARDT'S DISEASE



Stargardt's Disease is one of the most common **inherited juvenile macular degenerations**.

Transmission is usually recessive and related to the ABCA4 gene.

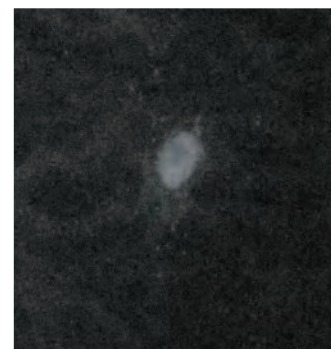
An autosomal dominant Stargardt-like macular dystrophy is related to the ELOVL4 gene.



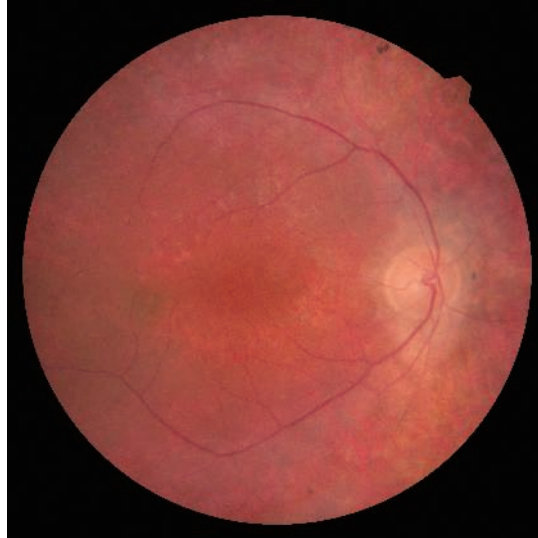FAF images show hypo-fluorescent areas in the macular region corresponding to large **macular atrophy**. The OCT B-scan shows **hyper-transmission** of light for the entire width of the image.

A **hyper-fluorescent** spot in the foveola indicates **RPE cells** that still contain residual lipofuscin.

This hyper-fluorescence can only be visualized with **green-FAF**. On blue-FAF, it would be completely obscured by the central dark spot.

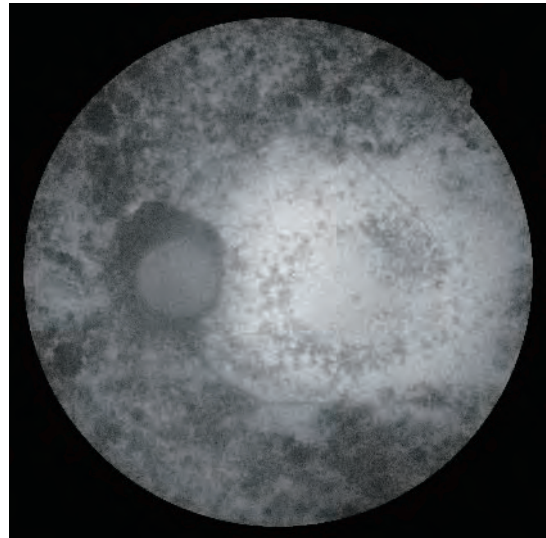
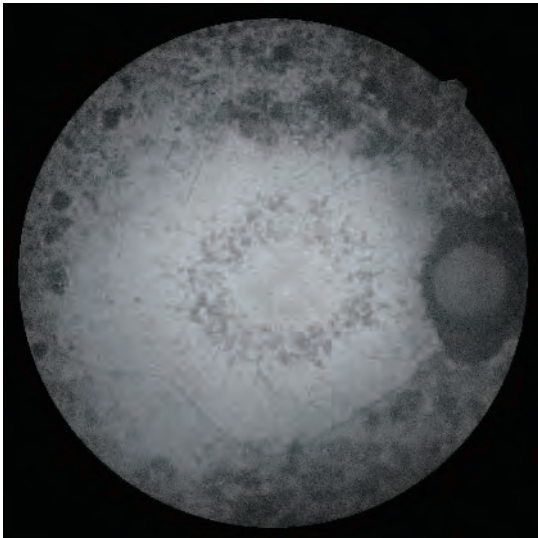


RETINITIS PIGMENTOSA



Retinitis Pigmentosa refers to a group of inherited diseases.

Color fundus picture shows a typical fundus with retinitis pigmentosa peripheral bone spicules and a **heterogeneous posterior pole**.



Green-FAF shows **bilateral retinitis pigmentosa**, with symmetrical changes. Hypo-fluorescent areas represent a lack of RPE cells.

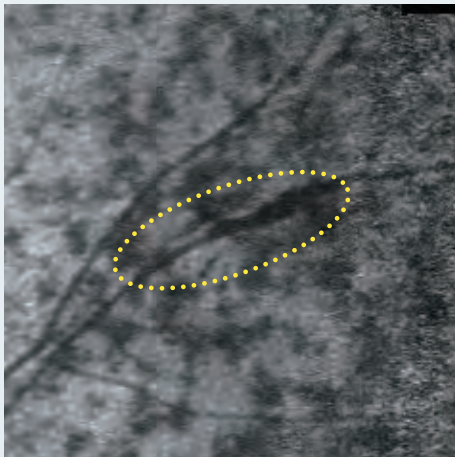
Dark areas along the vessels in the periphery are **bones spicules** (as in the top left image on the next page).

The **hypo-fluorescent** RPE mottling is similar in appearance to the pattern in the macular area of the teleangiectasia case but differs from **hyper-fluorescence** in AMD or pattern dystrophy.

Interpretation Tips

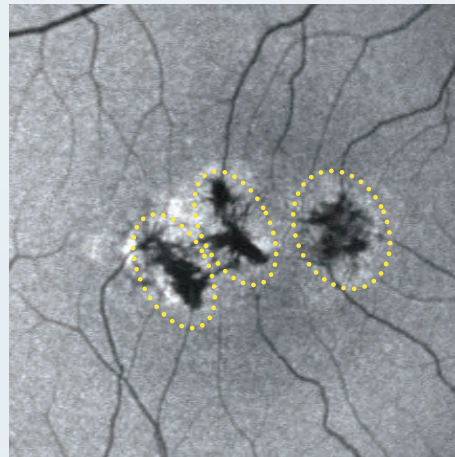
Retinitis Pigmentosa

(acquired with the Retina Scan Duo)



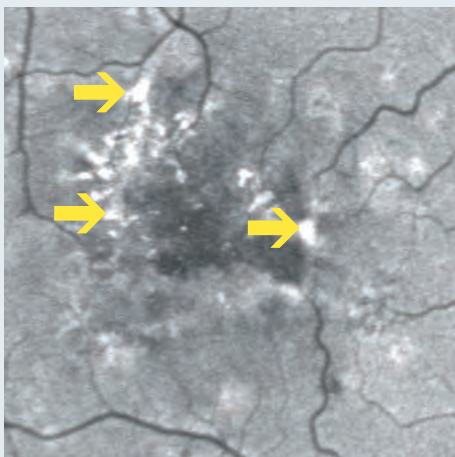
Macular TeleAngiectasia

(acquired with the previous NIDEK SLO product)



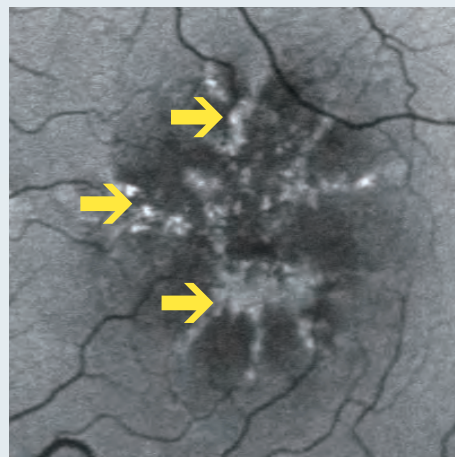
AMD

(acquired with the previous NIDEK SLO product)

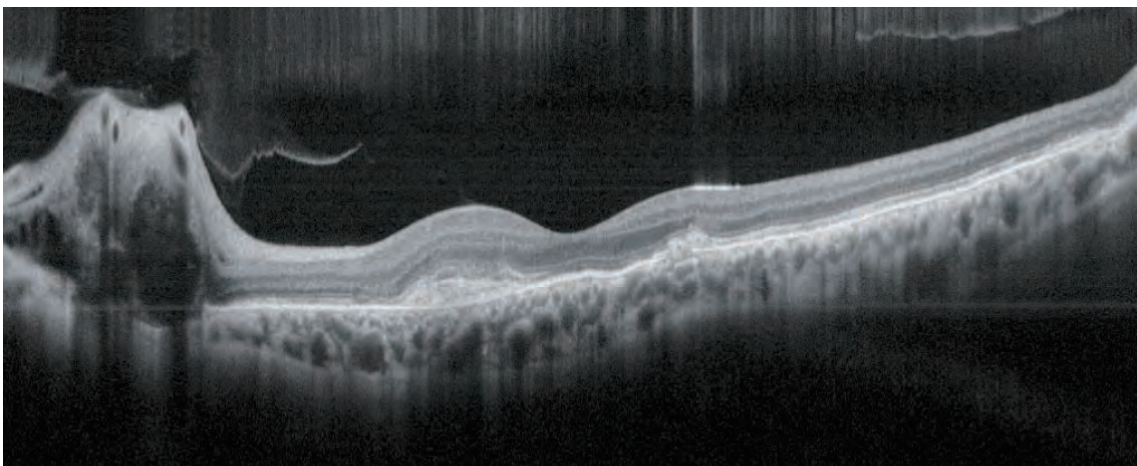
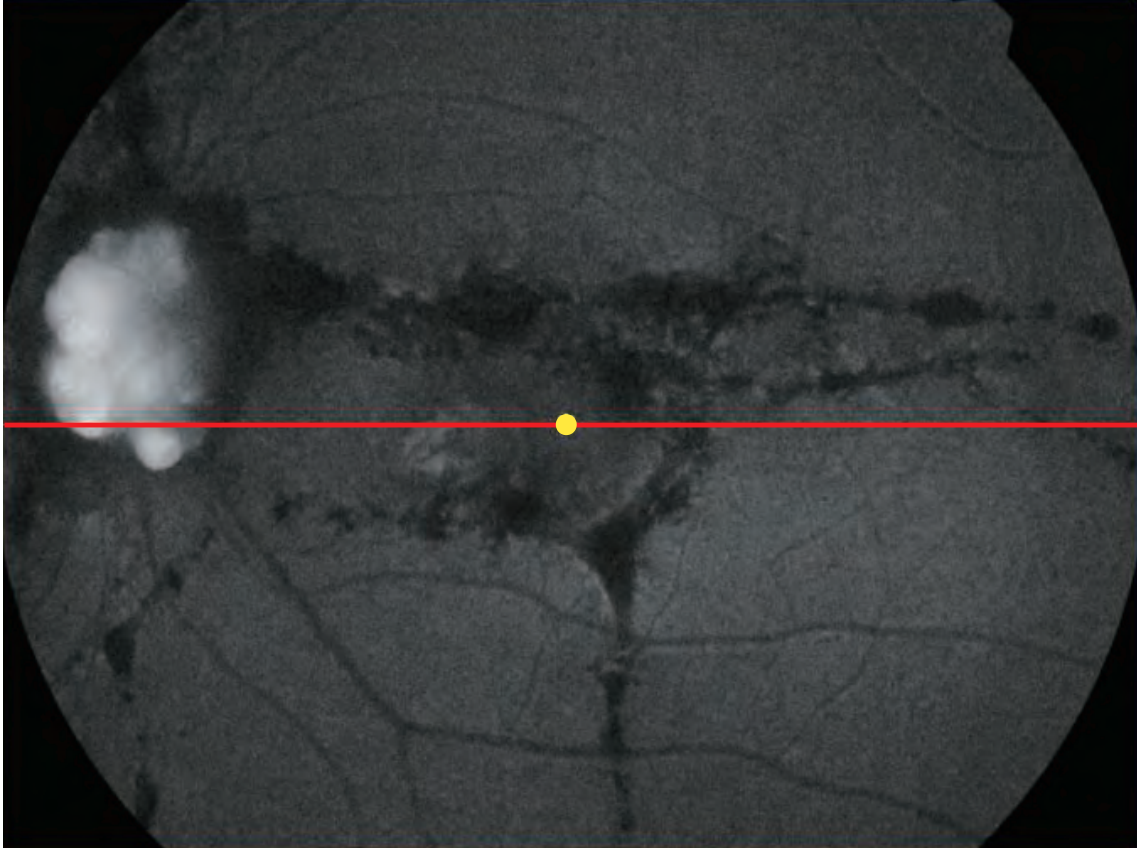


Pattern Dystrophy

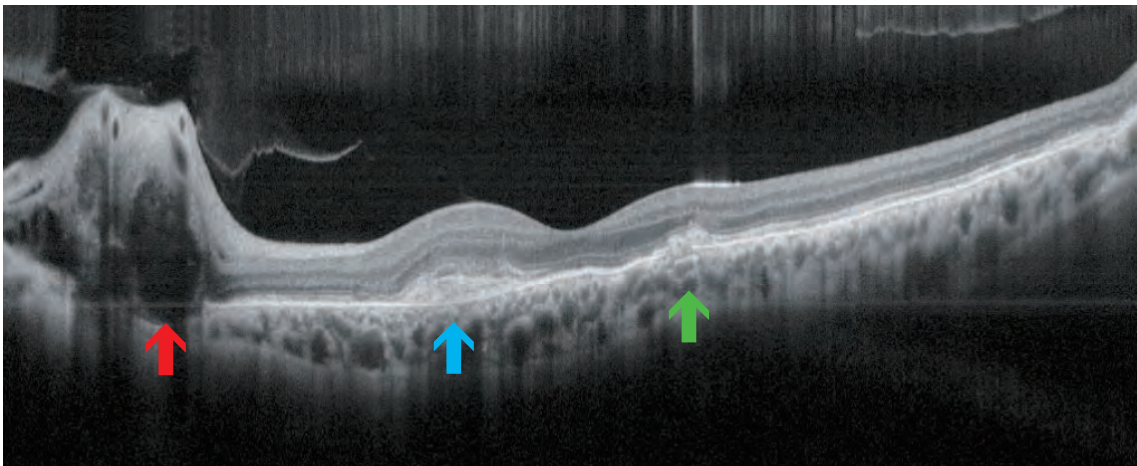
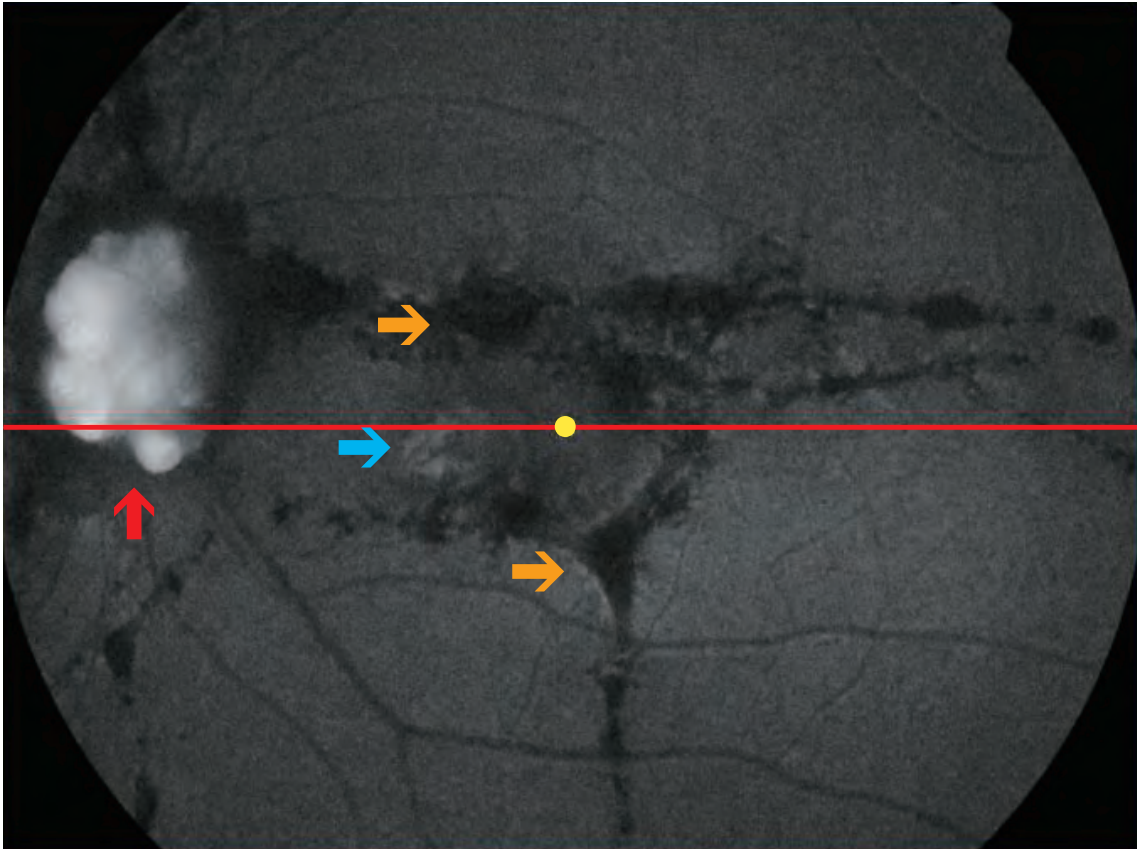
(acquired with the previous NIDEK SLO product)



ANGIOID STREAKS



Angioid Streaks are bilateral, narrow, irregular lines in the deep retina originating around the optic disk and distributed radially. They occur due to breaks in a **weakened Bruch's Membrane**. There are several systemic diseases associated with angioid streaks, the most common being pseudoxanthoma elasticum.

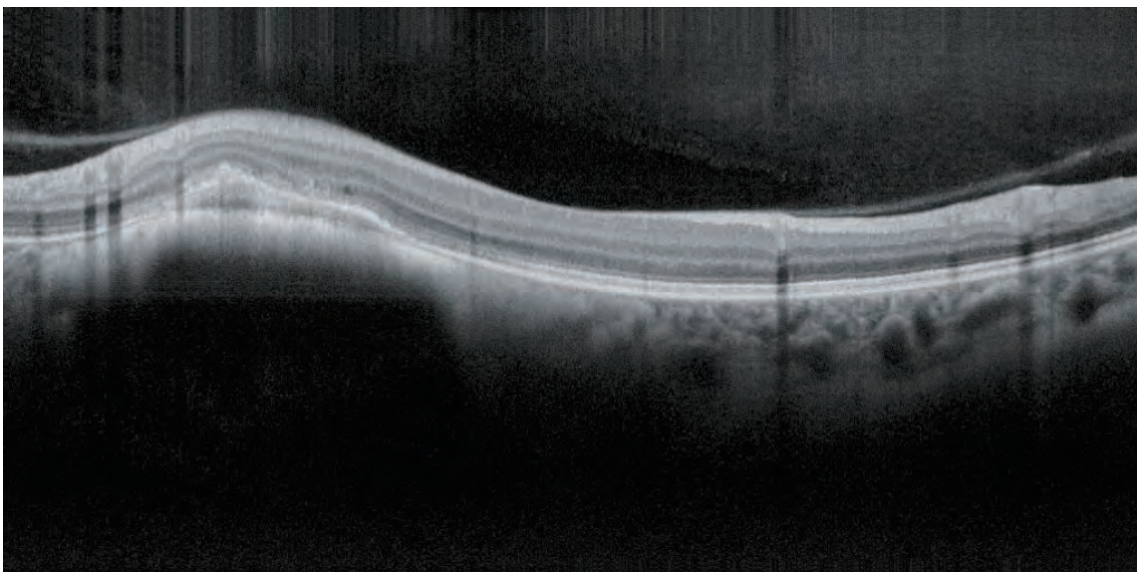
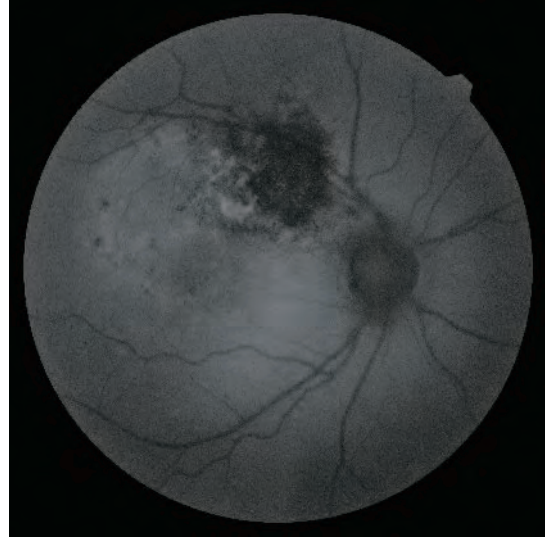
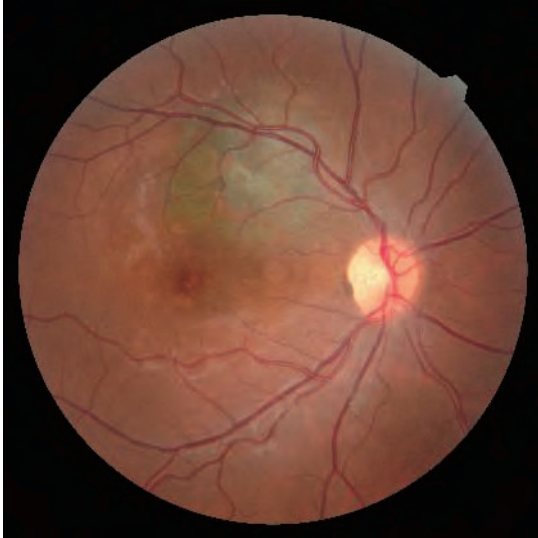

Angioid streaks can be diagnosed clinically.

The FAF appearance of angioid streaks (orange arrows) is dark with slightly increased fluorescence at **fibrovascular scars** (blue arrow) and optic nerve head drusen can be present (red arrows).

OCT B-scan shows **Bruch's Membrane rupture** (green arrow) and the fibrovascular scar (blue arrow).

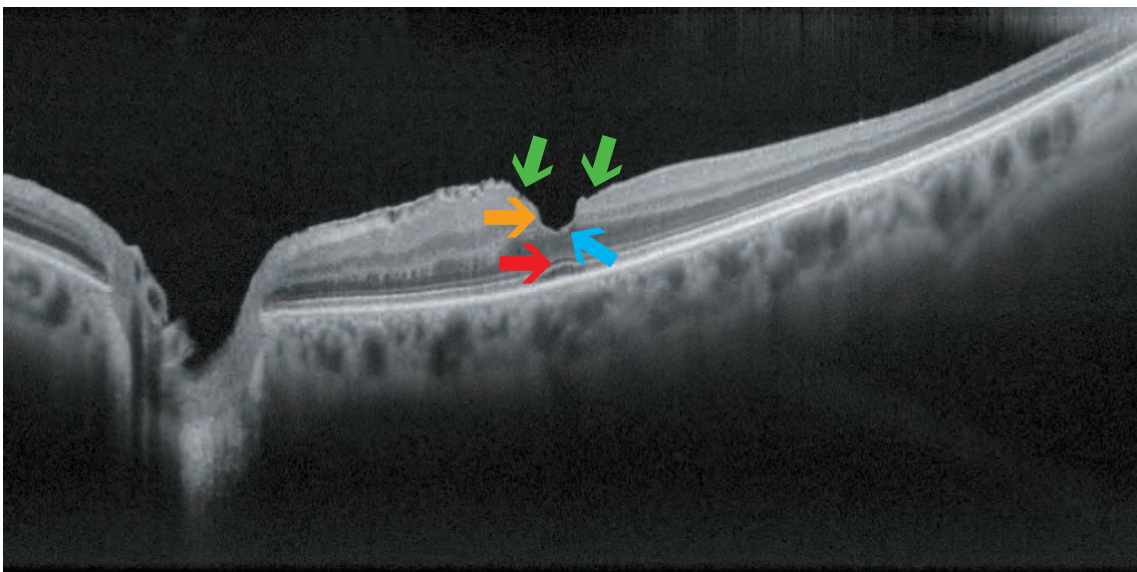
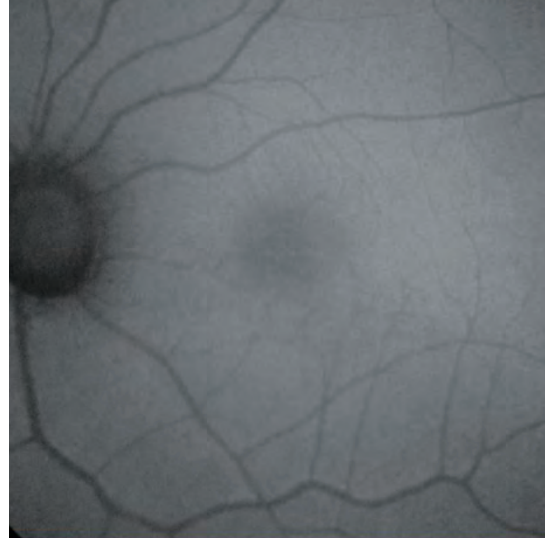
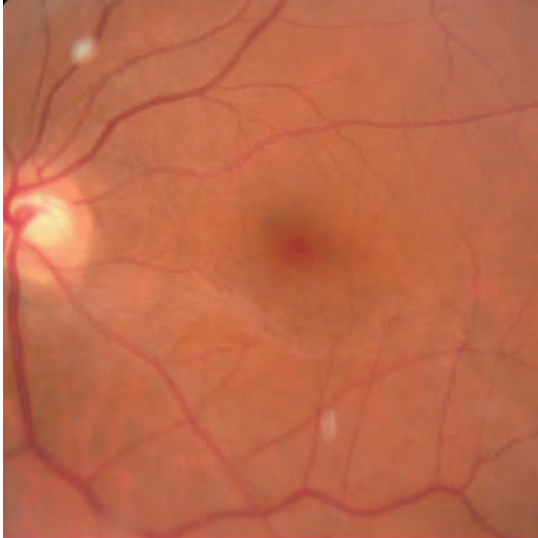CHOROIDAL MELANOMA



Choroidal Melanoma is one of the most common malignant **ocular tumors** that can spread systemically.

One sign of **malignancy** is the presence of **orange pigment** which is hyper-fluorescent in FAF images.

LAMELLAR MACULAR HOLE



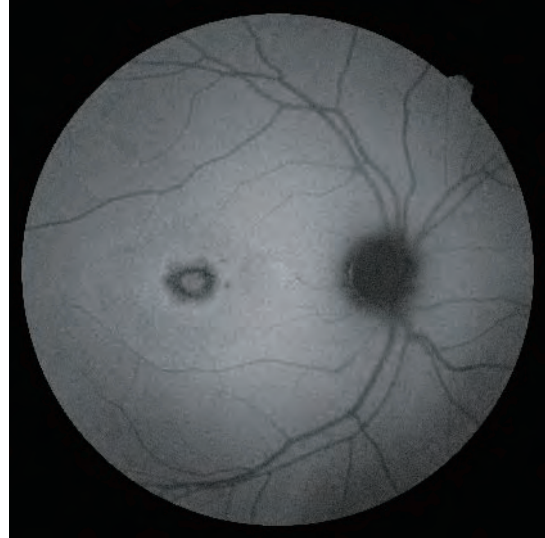
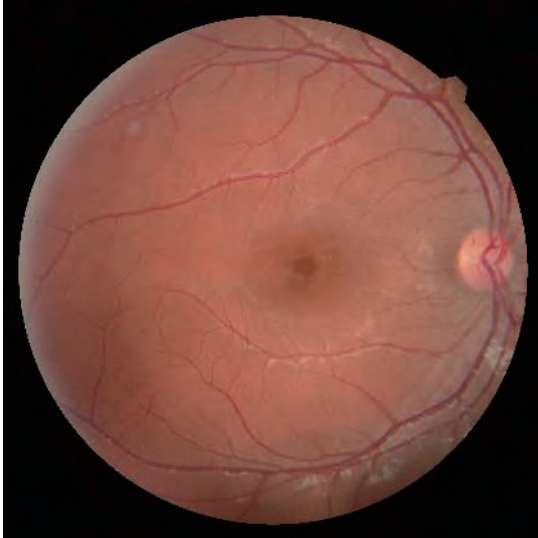Criteria for the diagnosis of **Lamellar Macular Hole** are as follows:

- **Irregular** foveal contour (green arrows)
- **Break** in the inner fovea (blue arrow)
- Intraretinal **split** (orange arrow)
- Intact foveal **photoreceptors** (red arrow)

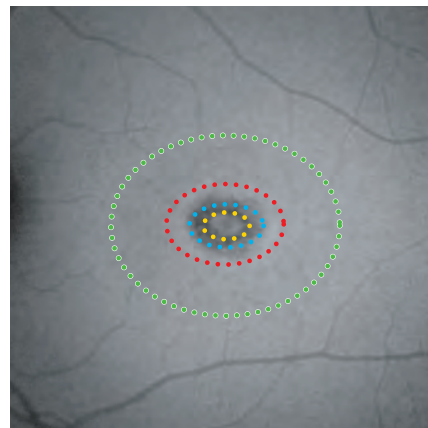
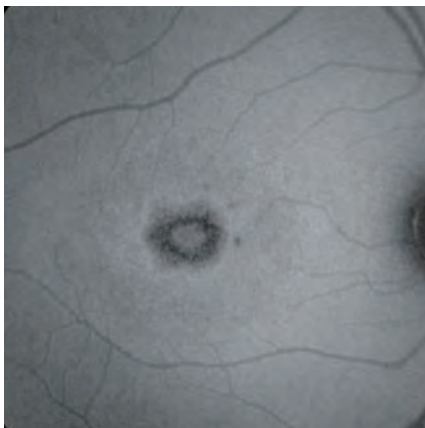
When analyzing a blue-**FAF image**, a lamellar macular hole produces an increased signal (hyper-fluorescent) in the foveal area (due to the lack of absorption normally due to macular pigment).

With **green-FAF**, the minor absorption effect would make the pathology less visible.

CONE DYSTROPHY



Cone Dystrophy is a general term used to describe a group of rare eye disorders affecting the cones. It is always **bilateral**. Cone dystrophies can be classified into 2 sub-groups: **stationary** and **progressive**. The **stationary** form tends to remain stable over time and is usually present at birth or develops in early childhood. The **progressive** form continuously evolves over time. Color fundus and FAF images are valuable in visualizing the changes in the affected area.



Green-FAF shows the bilateral disease that is perfectly **symmetric**.

Clinical features notable on the images include:

The ellipse of yellow-dots delineates **foveal sparing**.

The ellipse of blue-dots delineates the **atrophic macular area**, with hypo-fluorescence.

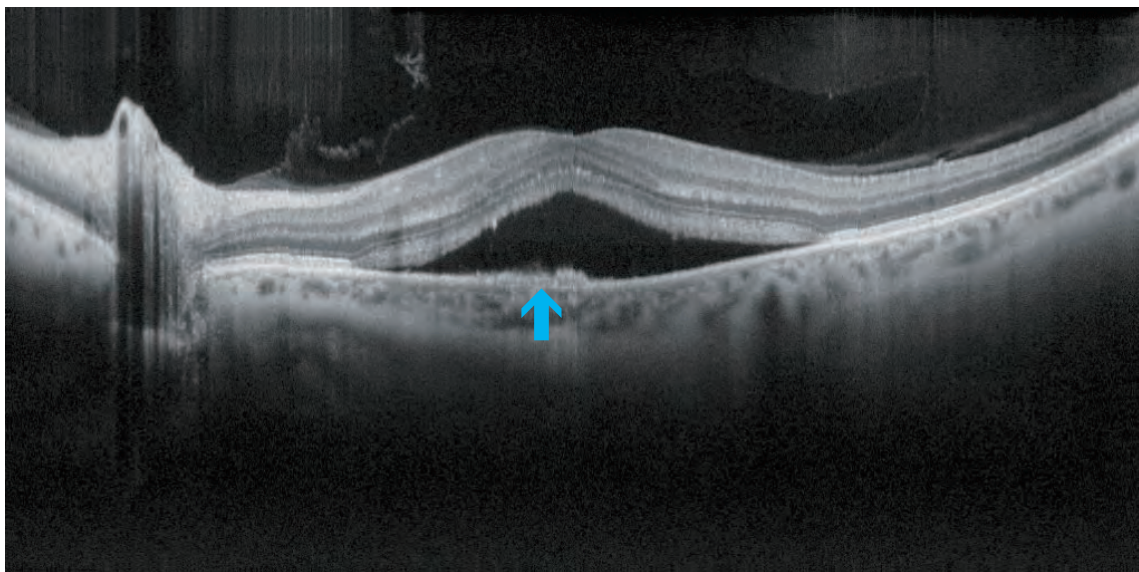
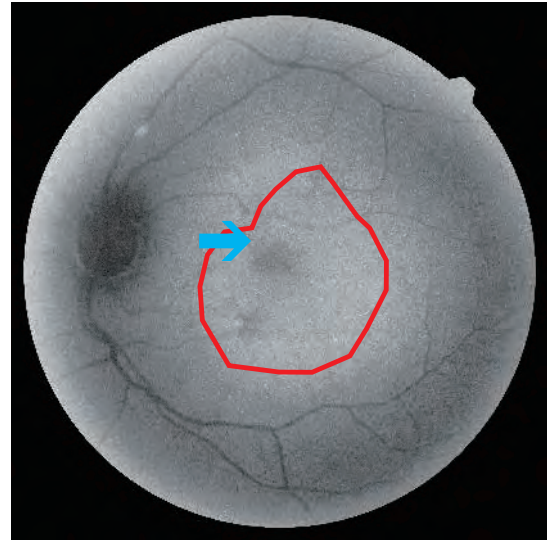
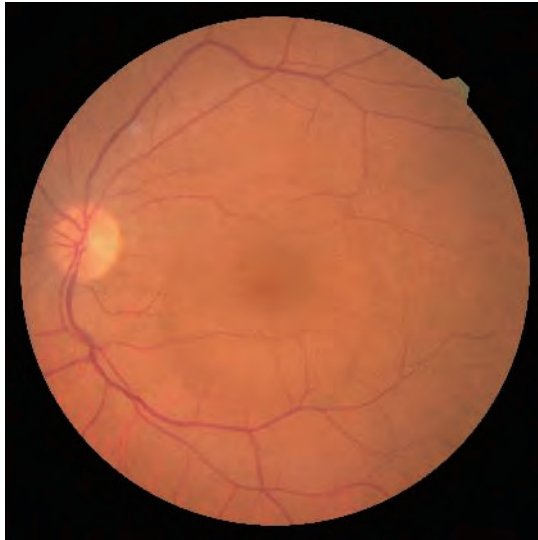The irregularity of the FAF signal indicates a sparse region of RPE cells.

The ellipse of red-dots delineates an area of **normal autofluorescence**.

The ellipse of green-dots delineates an area of **reduced autofluorescence**.

This FAF **pattern** is typical of cone dystrophies.

CENTRAL SEROUS CHORIORETINOPATHY



Central Serous Chorioretinopathy is a disease in which a serous detachment of the neurosensory retina occurs due to a **retinal pigment epithelium impairment**. It is also normally associated with increased permeability of the **choroid**.

There are two forms: **acute** and **chronic**.

In chronic central serous chorioretinopathy, FAF shows **hyper-fluorescent** areas below the detached retina due to the increased visualization of RPE fluorescence.

Hypo-fluorescence is due to atrophy.

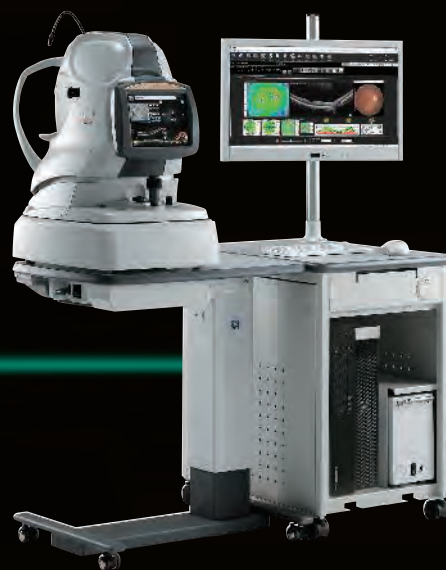Giovanni Staurenghi, MD

Marco Pellegrini, MD

Mariano Cozzi, MSc

Eye Clinic, Department of Biomedical and Clinical Science

"Luigi Sacco" Hospital, University of Milan, Italy



OCT / Fundus Camera
Retina Scan Duo™ 2

Brochure and listed features of the device are intended for non-US practitioners.



More clinical information available online

<https://www.nidek-intl.com/education/>

