



# Color SLO Atlas

Mirante

Shozo Sonoda, MD, PhD

Brochure and listed features of the device are intended for non-US practitioners.



More clinical information available online

<https://www.nidek-intl.com/education/>

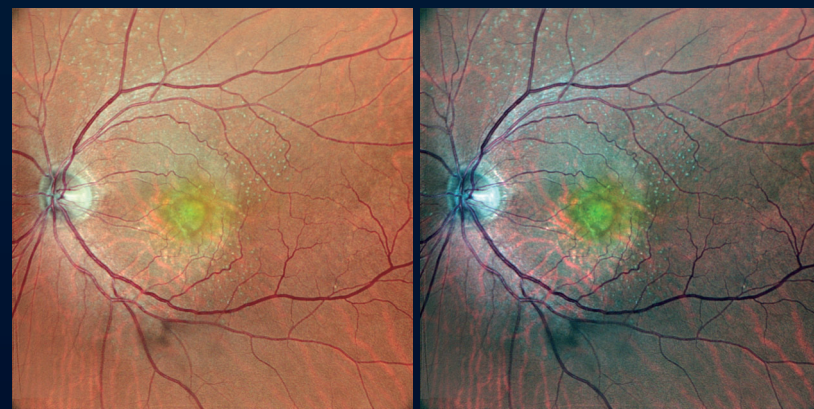



# Fundusphotomography\*

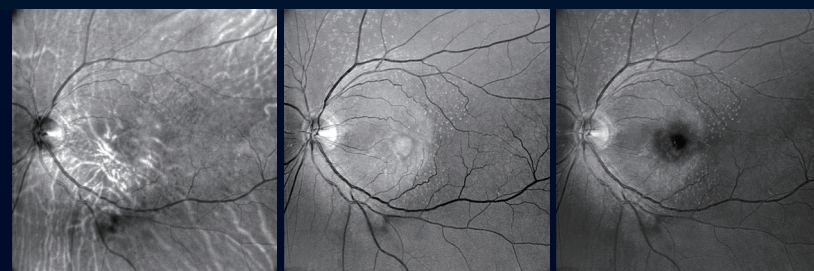
High definition, color SLO offers new possibilities for image interpretation by enhancing fundus details with a rich variation of color tones, differing from conventional fundus images.

\*A coined term for fundus photography and tomography.



Fundus camera display

RGB contrast-optimized display



Red

Green

Blue

Color SLO  
&  
RGB SLO

FA/ICG

Multimodal Fundus  
Imaging

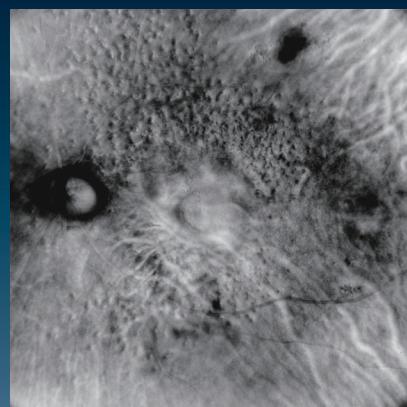
Fundus  
Autofluorescence  
Green/Blue

Retro mode

OCT  
&  
OCT-Angiography

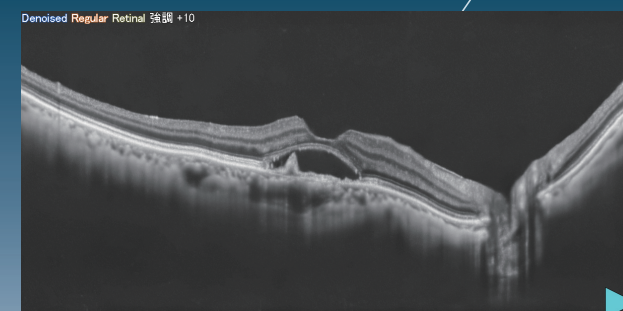
## Retro mode

Presents a characteristic fundus lesion using infrared SLO imaging.

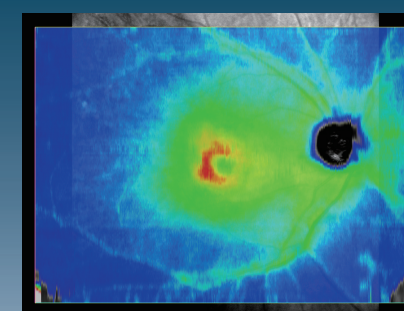


## OCT

Allows widefield and high-definition tomography imaging.



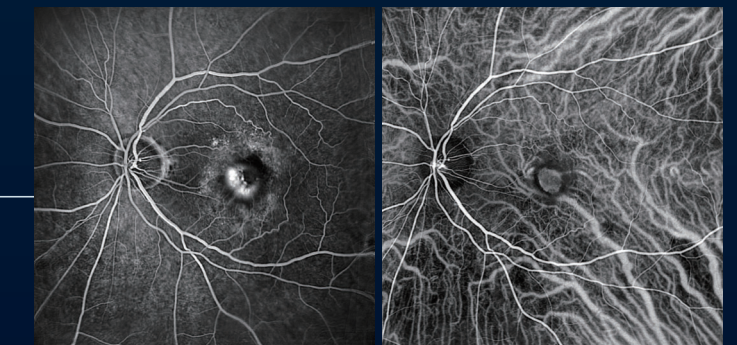B-scan



16.5 x 12 mm ILM-RPE/BM

## Contrast Angiography

Effective for evaluating retinal blood flow using contrast dye to generate high-definition images.

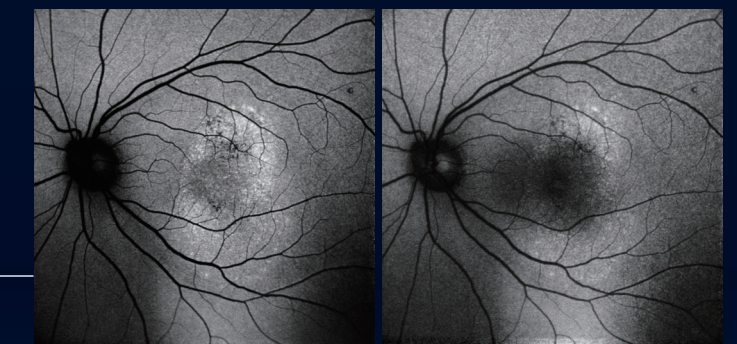


FA

ICG

## Fundus Autofluorescence

Used to evaluate lipofuscin in the pigment epithelium using two different wavelengths to detect autofluorescence.

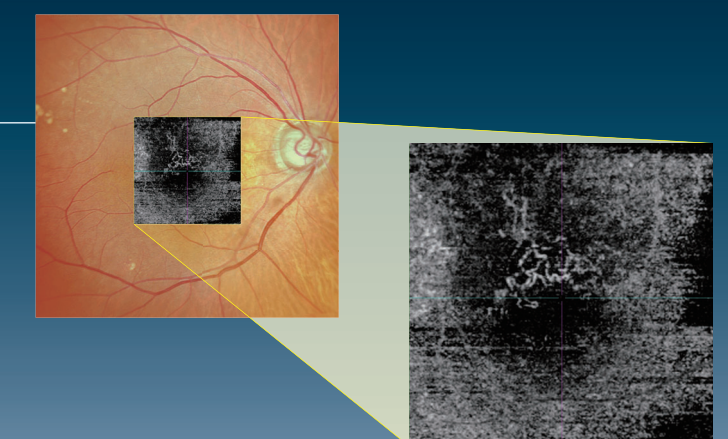


Green

Blue

## OCT-Angiography (optional)

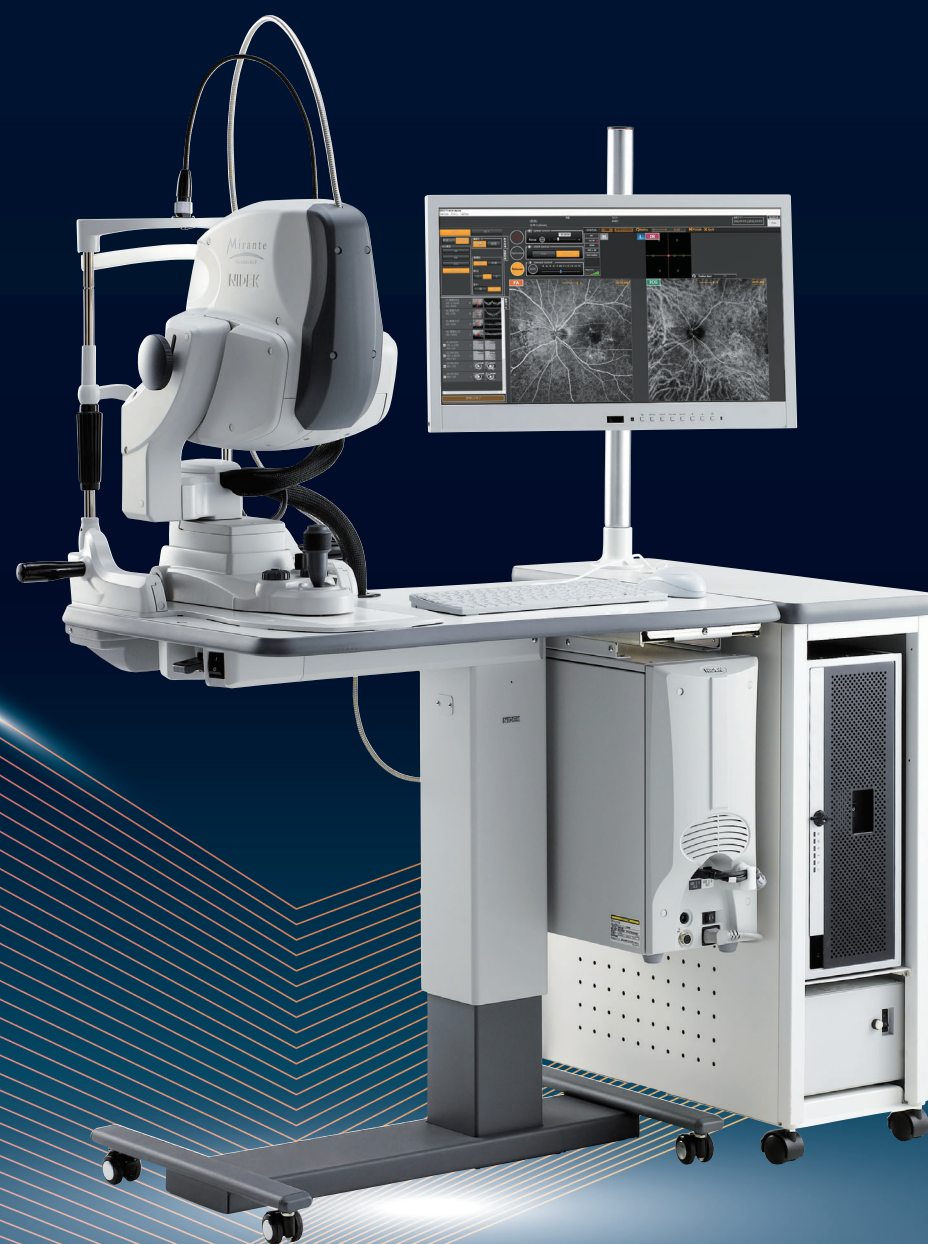Effective for evaluating fundus microvasculature and abnormal blood flow.





# Mirante

FA/ICG/OCT




	Page
Why Choose Color SLO Now? —————	7
Peripheral Retinal Imaging with Widefield Color SLO ———	8
High-Definition Color SLO —————	9
Features of Mirante Explained from the Imaging Principle —	11
What Is Fundusphotomography? —————	11
Interpretation of Fundusphotomography —————	12
Epiretinal Membrane —————	13
Early Glaucoma with Retinal Nerve Fiber Layer Defect ———	14
Diabetic Retinopathy with Dot Hemorrhage and Exudate —	15
Vitreous Hemorrhage Associated with Proliferative Diabetic Retinopathy —————	16
Proliferative Diabetic Retinopathy —————	17
Retinal Vein Occlusion —————	18
Central Retinal Vein Occlusion —————	20
Early Age-Related Macular Degeneration —————	21
Atrophic Age-Related Macular Degeneration —————	22
Exudative Age-Related Macular Degeneration —————	23
Exudative Age-Related Macular Degeneration (Associated with Pachychoroid) —————	26
Retinal Microaneurysm Rupture —————	27
Observation of Changes over Time: Retinal Microaneurysm Rupture —————	28
Observation of Changes over Time: Polypoidal Choroidal Vasculopathy —————	29
Observation of Changes over Time: Leukemic Retinopathy, Cat-Scratch Disease —	30
Central Retinal Artery Occlusion —————	31
Asteroid Hyalosis —————	32
Vitreomacular Traction Syndrome —————	33
Vogt-Koyanagi-Harada Disease —————	34
IOL Dislocation —————	34
Pit Macular Syndrome —————	35
Optic Disc Melanocytoma —————	35



The evolution of fundus imaging equipment such as widefield fundus imaging, optical coherence tomography (OCT), OCT-Angiography, has been remarkable with the current devices enabling rapid acquisition of high-definition retinal images. While this benefits patients through improved diagnostic outcomes, there is an issue of “physicians having to assess an ever-increasing quantity and variety of medical images” and the related possibility of overlooking important details. With the conventional image interpretation paradigm, assessing a greater number of images extends office hours which can lead to a significant overburden of work for medical personnel. Hence, a potential solution is the introduction of all-in-one imaging devices and the establishment of medical assessment standards that include these multifunction devices.

The “widefield laser ophthalmoscope” incorporated in the Mirante is at the forefront of addressing this issue. For example, as a multimodal device the Mirante acquires high-definition, widefield fundus images that present more information than conventional fundus cameras. Understanding the principles of this scanning laser ophthalmoscope (SLO) and familiarity with image interpretation enables timely and efficient identification of subtle retinal lesions without overlooking important characteristics. Additionally, the clear high definition images generated by the Mirante facilitate easy patient education thereby encouraging them to participate in treatment.

We hope that this clinical atlas centered on the Mirante’s color SLO modality will aid our colleagues worldwide to become familiar with this novel unique device and the diagnostic possibilities for chorioretinal pathology and management.



**Shozo Sonoda,**  
MD, PhD

Director, Kagoshima Sonoda  
Eye Clinic & Plastic Surgery,  
Japan

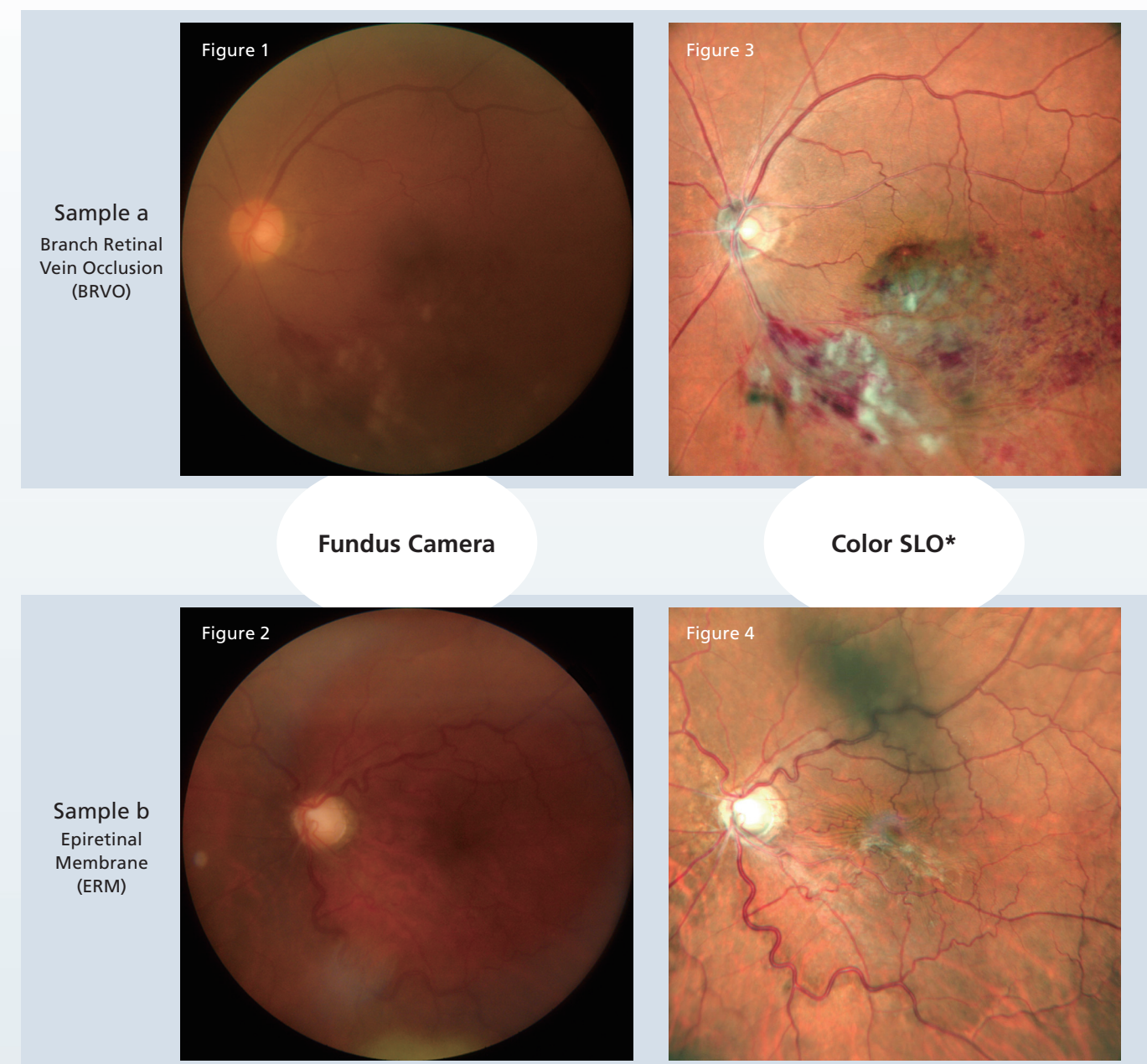
Visiting Professor,  
Department of Ophthalmology,  
Kagoshima University, Japan

Biography	1996	Graduated from Ehime University School of Medicine
	1996	Department of Ophthalmology, Kagoshima University Hospital
	2000	Completion of Residency, Kagoshima University School of Medicine
	2000	Assistant, Kagoshima University Hospital
	2007	International Training, Doheny Eye Institute
	2009	Assistant Professor, Department of Ophthalmology, Kagoshima University Graduate School of Medical and Dental Sciences
	2015	Instructor, Department of Ophthalmology, Kagoshima University Hospital
	2018	Clinical Associate Professor, Department of Ophthalmology, Kagoshima University Hospital
	2020	Director, Kagoshima Sonoda Eye Clinic & Plastic Surgery,
		Visiting Professor, Department of Ophthalmology, Kagoshima University



## Why Choose Color SLO Now?

The fundus camera is a fundamental device for ophthalmic examination because it acquires images of fundus lesions in a non-invasive manner. It has historically been used for screening and documenting fundus findings. However, due to the imaging principle, unclear retinal images can occur in the presence of cataracts or other ocular opacities (Figure 1). Another drawback is a loss of peripheral focus as it is easily affected by pupil diameter (Figure 2). Hence, images from a fundus camera can be suboptimal or it may be impossible to acquire images due to these drawbacks. Therefore, some lesions may not be adequately imaged for clinical assessment if only a fundus camera is used.



\*Photo: Mirante standard 60° (central angle of view 89°)

The Mirante SLO addresses the inherent drawbacks of the imaging principles of the fundus camera and can display the fundus in “color”. Incorporating remarkable technological advances and improvements in device performance, the Mirante displays clear images even in cases where a fundus camera would be suboptimal (Figure 3 and 4).

**A color SLO provides a host of anatomical information and this modality is expected to gain greater clinical utility in the future.**



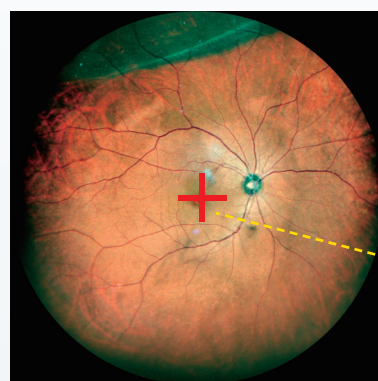
# Peripheral Retinal Imaging with Widefield Color SLO

A wide-field adapter\*<sup>1</sup> enables image capture out to 110° (central angle of view 163°) without mydriasis. The vortex veins can be imaged with central fixation by using the wide-field adapter. The standard 60° (central angle of view 89°) image acquisition captures the entire optic disc and the vascular arcades, which is suitable for detailed observation of lesions in the posterior pole.

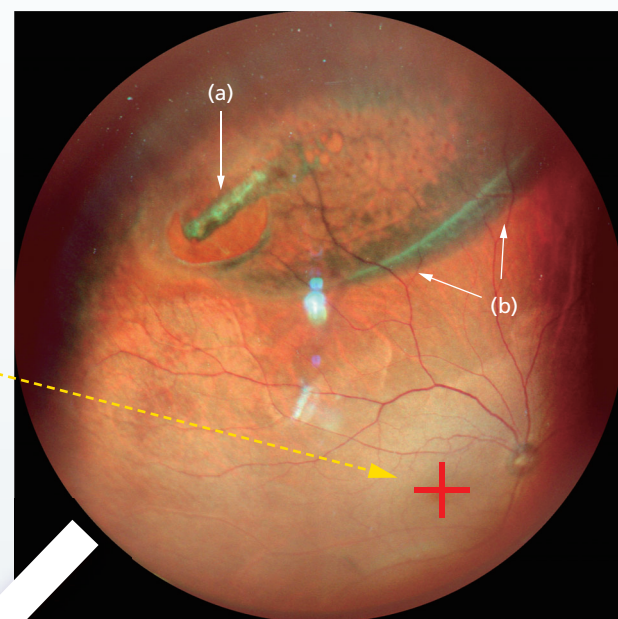
**Case 1** Image capture with central fixation\*<sup>2</sup> confirmed localized retinal detachment in the upper periphery. Shifting the position of the internal fixation marker allowed assessment of the full extent of the retinal tear (a) and area of retinal detachment (b) and lattice degeneration in the fundus.

62-Year-Old Female

\*<sup>1</sup> Optional  
\*<sup>2</sup> Widefield 110°  
(central angle of view 163°)

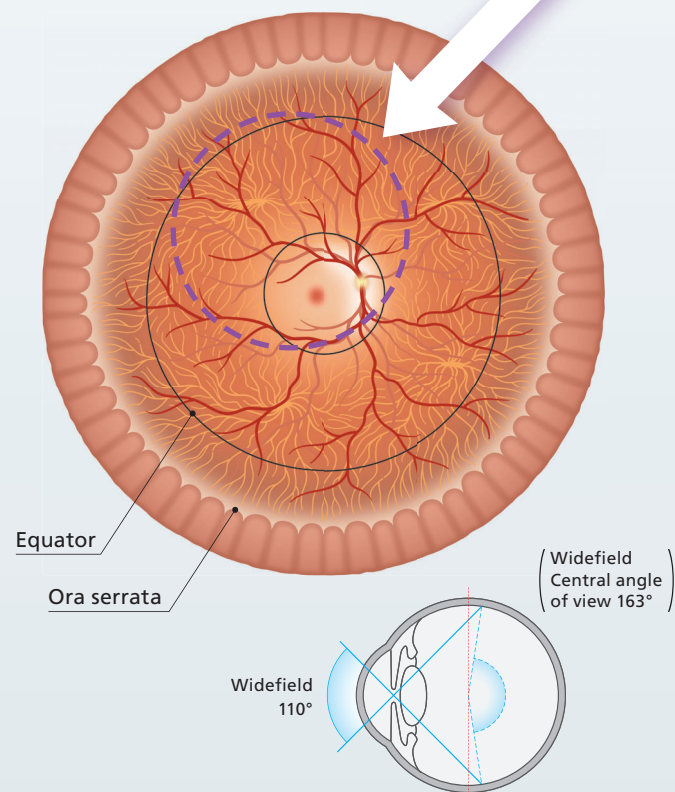


Central fixation

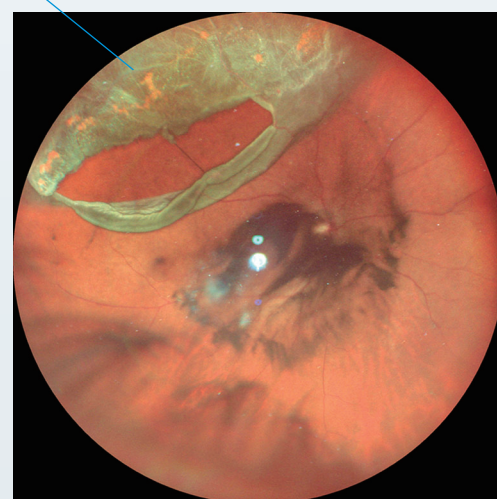

Imaging by shifting the internal fixation marker downwards

The wide-field adapter enables imaging of the retinal periphery (widefield 110° [central angle of view 163°]) that crosses the equator and approaches the ora serrata.



The detached area is cloudy and appears slightly yellowish-green



**Case 2**

55-Year-Old Male

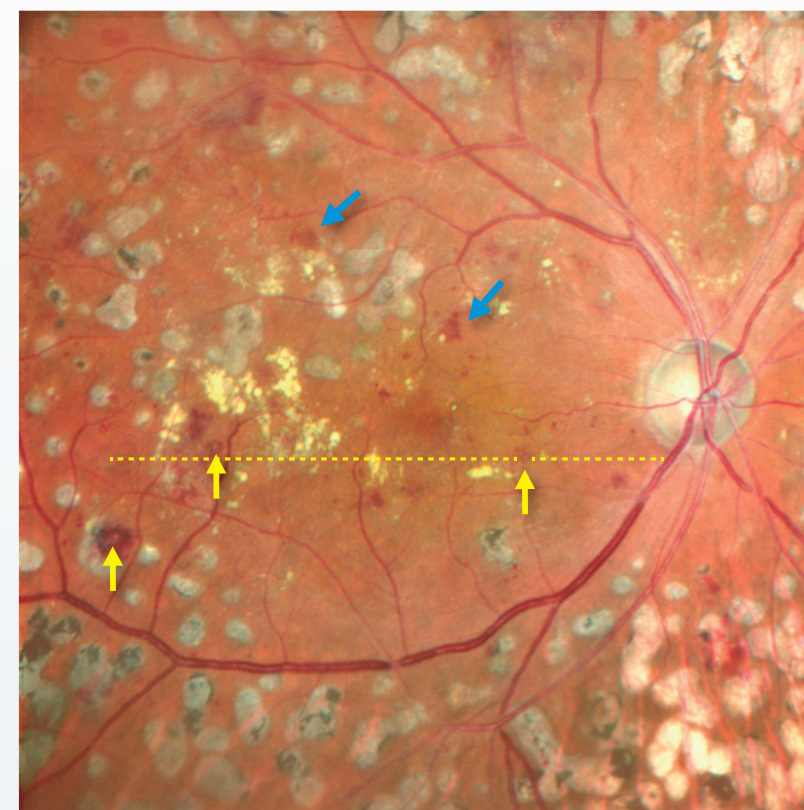
Confirmation of retinal detachment, a tear and posterior vitreous opacity associated with posterior vitreous detachment

# High-Definition Color SLO

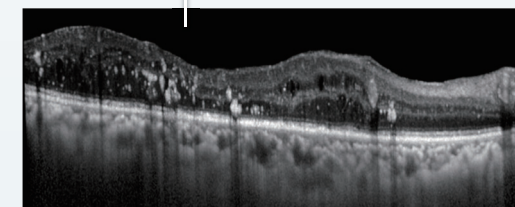

**Case 3**

70-Year-Old Male

This case of non-proliferative diabetic retinopathy and diabetic macular edema (DME) illustrates the high-definition imaging that can be used to assess findings (bleeding, hard exudate, laser photocoagulation scars, etc.). Retinal hemorrhage (blue arrows) or microaneurysm (MA) (yellow arrows) can be identified in this color SLO image. A typical MA shows a white hyper-reflective area within the red lesion (yellow arrows).



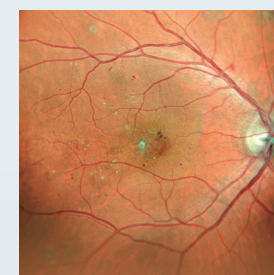
Standard 60° (central angle of view 89°)



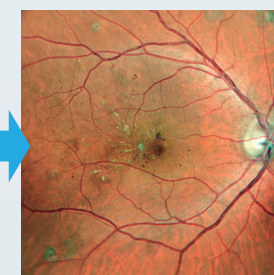
**Case 4**

48-Year-Old Male

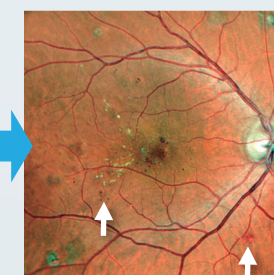
This case of diabetic maculopathy and non-proliferative diabetic retinopathy shows the changes over time in the shape of the MA and hard exudate proximal to the macula. The appearance of a new retinal hemorrhage (white arrows) was confirmed during the course of this investigation. In addition to the feature of being able to observe the fundus at once, color SLO fundus can record lesions in high-definition, follow-up imaging can be performed to review any subtle changes in pathology over time.



Initial visit

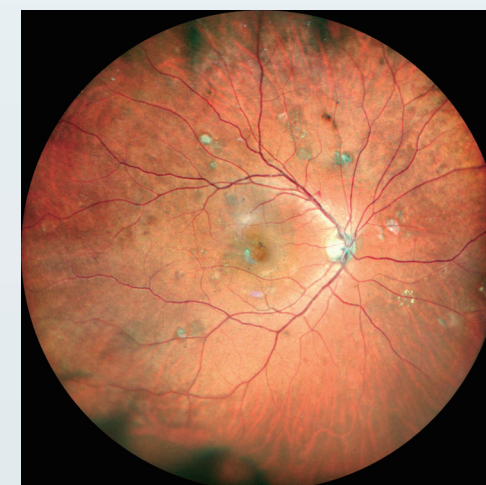

1 month later



2 months later

Standard 60° (central angle of view 89°)



Widefield 110° (central angle of view 163°)

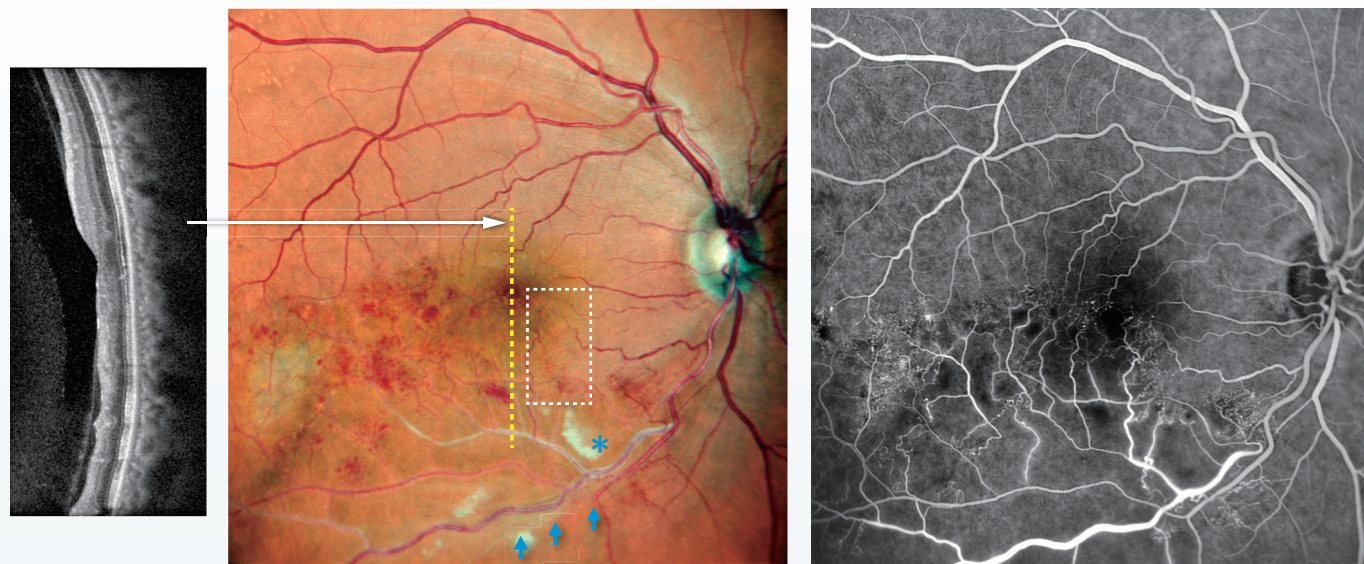


# High-Definition Color SLO

## Case 5

62-Year-Old Female

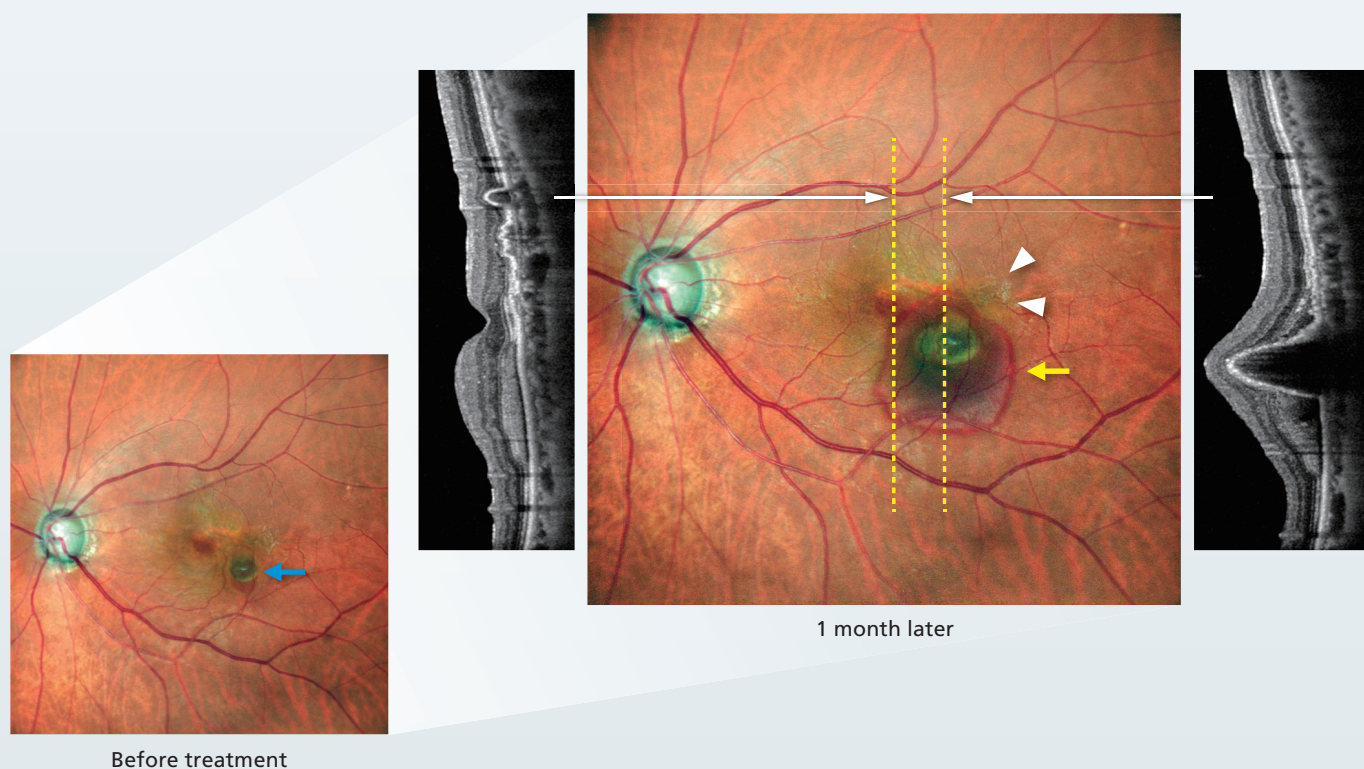
An imaging study with the Mirante, 5 months after the onset of branch retinal vein occlusion (BRVO) shows that soft exudate (blue asterisk) and retinal hemorrhage remain. Comparison with OCT and fluorescein angiography (FA) using the Mirante, indicates that the color tone of the area of non-perfusion differs from the normal superior retina. Evaluation of the vascular morphology indicates that the occluded blood vessels (blue arrows) are white, and capillary dilation is present (within the rectangle).



## Case 6

81-Year-Old Male

A case of age-related macular degeneration (AMD) and polypoidal choroidal vasculopathy (PCV). Before treatment (left figure), polyp enlargement (blue arrow) was observed. One month after anti-VEGF therapy, blood was present from the polyp (yellow arrow). Evaluation of the color SLO image and OCT imaging indicates the presence of a relatively high pigment epithelial detachment (PED) and a branching vascular network vessel. Although not directly related to AMD, there is also an epiretinal membrane (ERM) (white arrowheads) at the posterior pole.

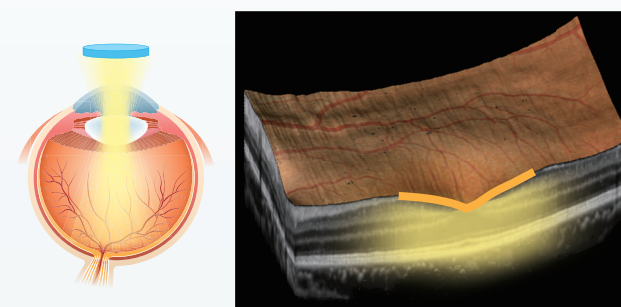


# Features of Mirante Explained from the Imaging Principle

Color SLO produces fundus images by scanning the retina with a laser beam in a fast and accurate manner. The imaging range is determined by the scanning angle (scanning width). As high-contrast information is obtained for each scanned point, it also has the advantage of displaying a clearer image on the entire screen.

## Principle and Features of a Fundus Camera

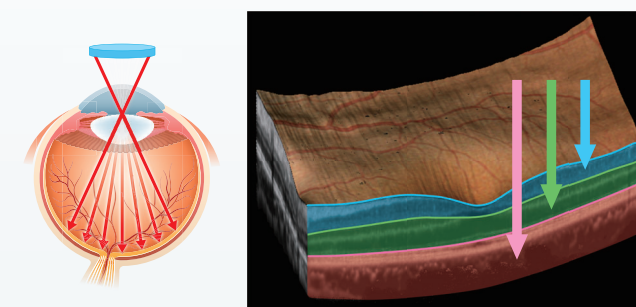
- Depending on the pupil diameter, the imaging range is determined by the extent of the illumination from the flash lamp that reaches the center of the fundus (the peripheral area becomes darker).
- The focus is on the center of the imaging lens (it loses focus in the periphery).
- The light flash is composed of components of various wavelengths and detects all of the information in the area that is illuminated (contrast decreases due to the increasing amount of information).



The light from the flash lamp is optimally focused and brighter in the center.

## Principle and Features of Color SLO Fundus Imaging

- A laser with a specific wavelength can reliably and accurately scan out to the retinal periphery without dependence on the pupil diameter.
- The confocal principle is used for scanning the fundus and high contrast images are generated from the retinal center to the periphery.
- Mirante uses a laser with three different wavelengths with each wavelength reaching either the superficial, intermediate, and deep retinal layers; therefore, images that reflect the retinal depth can be obtained for each wavelength.

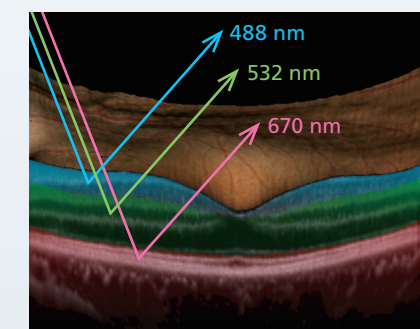


The extracted image changes for each retinal layer depending on the wavelength of the laser.

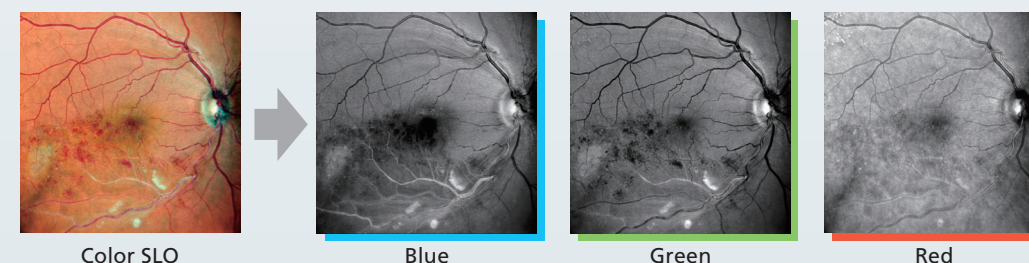
# What Is Fundusphotomography?

Fundusphotomography is a new term coined by the author that combines "fundus photography" and "tomography" to express the beneficial features of the color SLO fundus imaging equipment. It indicates that there is depth information despite being a fundus image, thereby facilitating acquisition of the combination of fundus image and OCT in what appears to be a single image.

More specifically, a color SLO fundus imaging device such as the Mirante uses multiple laser wavelengths to simultaneously produce high-contrast, monochrome SLO images and assigns each color to create a color fundus image. The images obtained for each wavelength reflect the information from different depths of the retina (right figure). If there is a lesion, the shade of the affected depth differs from normal, making it easier to spot the pathology. Additionally, since images are taken at a finer pitch compared to the planar resolution of conventional OCT, small, subtle lesions can also be depicted.



Mirante highlights images of different depths of the retina depending on the wavelength of the laser used.



Example using Case 5 of the differing images from each wavelength using SLO, with the blue wavelength highlighting soft exudate and areas of non-perfusion. Green highlights blood vessels and bleeding.



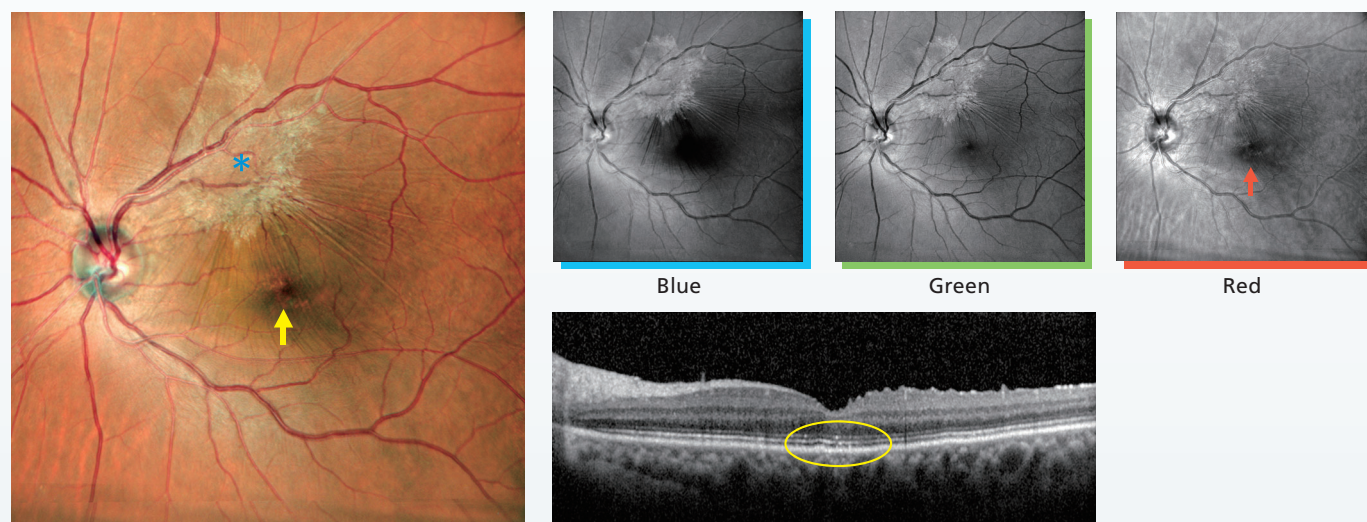
# Interpretation of Fundusphotomography

A single Mirante color SLO fundus image can be acquired quickly, allowing assessment of the nature and depth of a lesion.

## Case 7

57-Year-Old Male

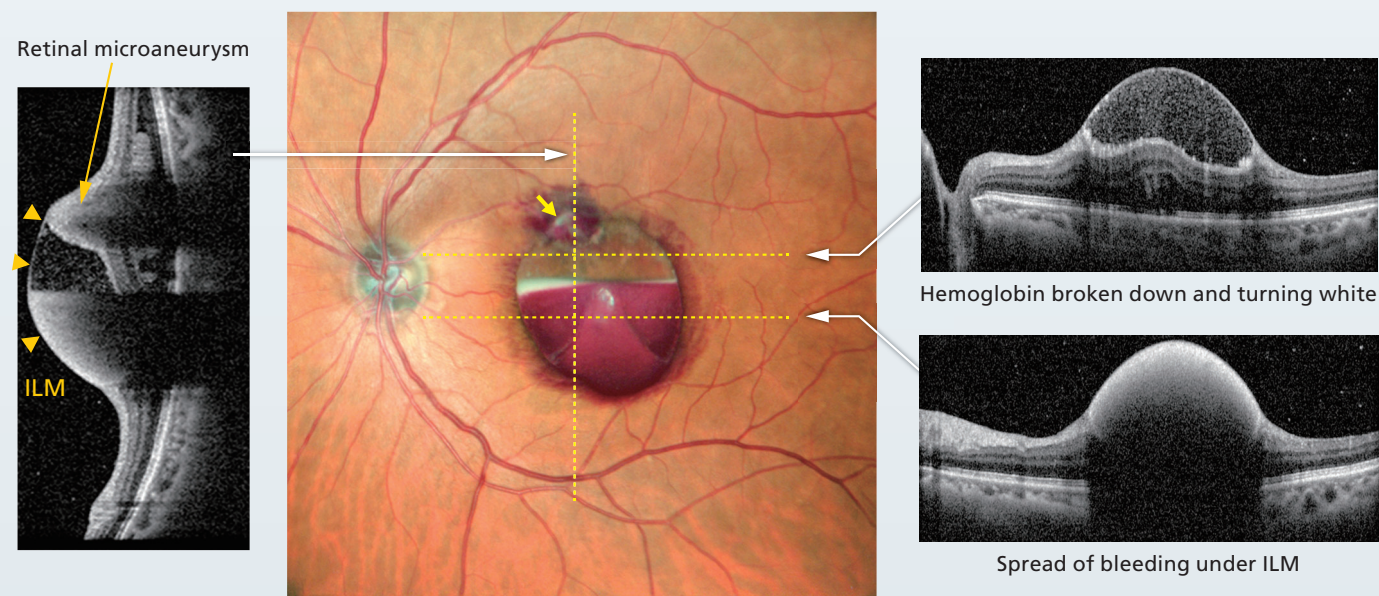
Case of epiretinal membrane (ERM) and retinal pigment epithelial cell abnormalities. The images show that the ERM and associated retinal folds are located near the superior vascular arcades (blue asterisk). The color tone of the macula appears irregular in the color SLO (yellow arrow). SLO images from each wavelength indicate that the ERM and retinal folds are best depicted with the blue wavelength. The red SLO image indicates an irregular signal (red arrow) in the macula corresponding to a slight irregularity of the retinal pigment epithelium (oval) confirmed by OCT.



## Case 8

82-Year-Old Female

Retinal microaneurysm rupture. In this case, the retinal microaneurysm (yellow arrows) is the source of the bleeding, and the blood under the internal limiting membrane (ILM) can be observed with excellent clarity. There is partial decomposition of hemoglobin turning white above the niveau formation. Comparison with the OCT findings indicates that blood is present under the ILM and the spread can be clearly determined in the color SLO.

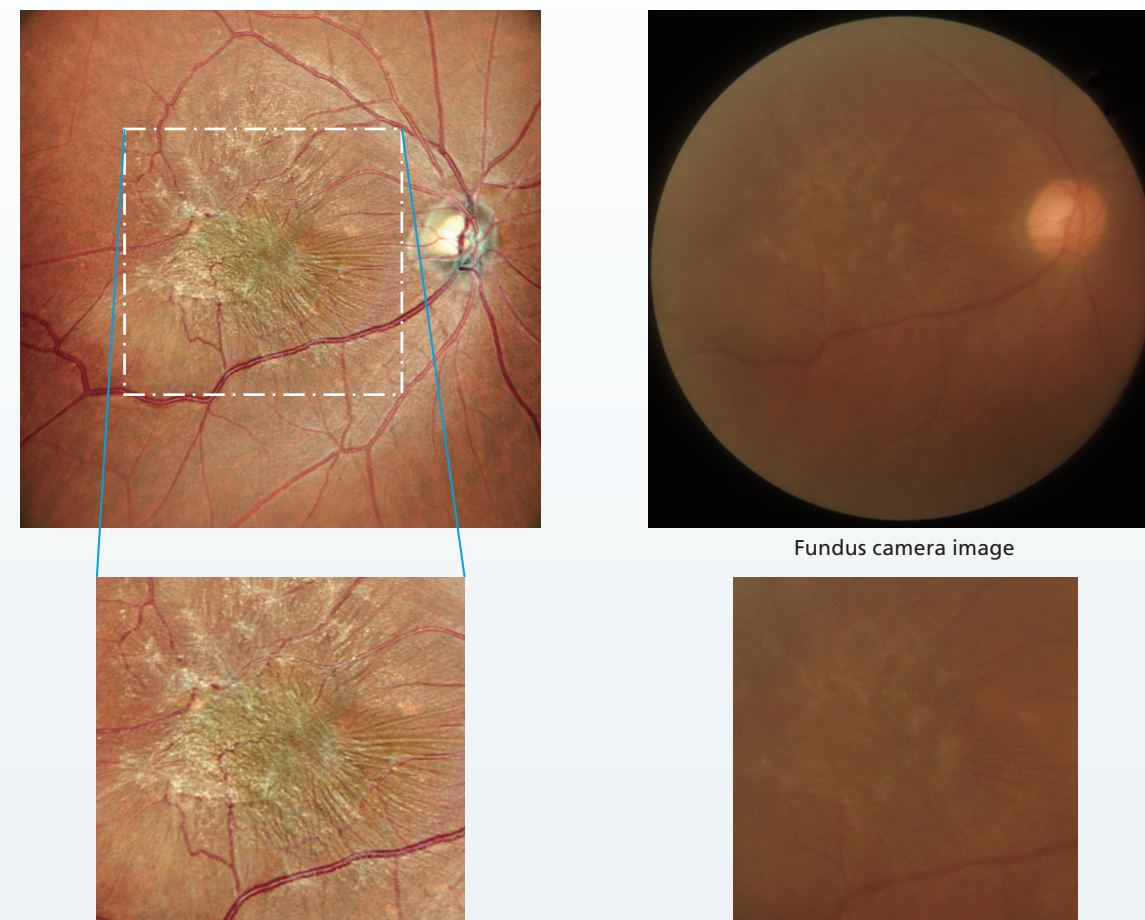


# Epiretinal Membrane

## Case 9

72-Year-Old Male

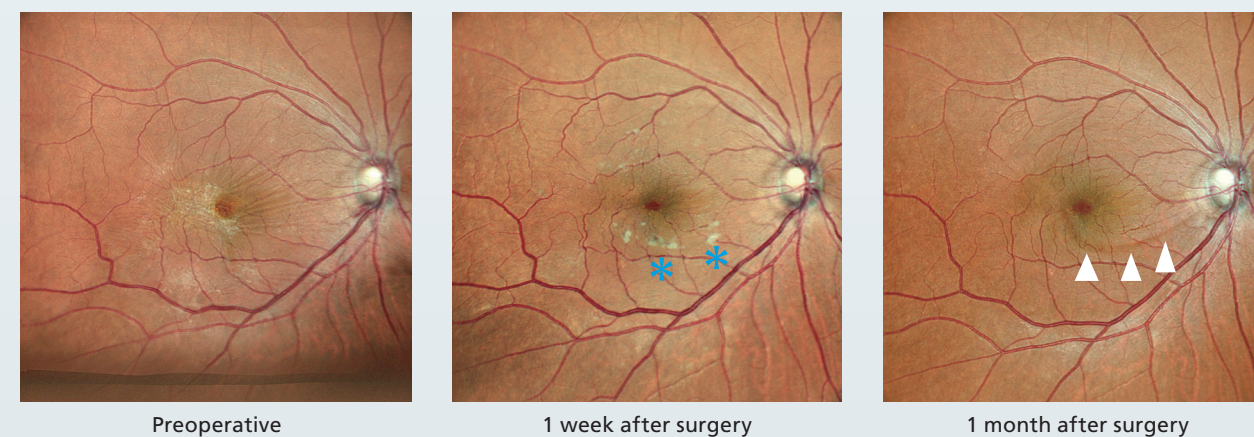
ERM can be detected by a fundus camera, however, in the presence of a cataract it is often difficult to assess the extent and nature of the membrane. Although imaging with OCT allows a rough estimation of the extent of the pathology, a color SLO enables observation of the entire ERM and the fine morphologic changes in the retina.



## Case 10

65-Year-Old Female

This patient presented with symptoms of distortion due to ERM (M-chart horizontal: 0.3, vertical: 0.5). Preoperative imaging indicated an ERM, and retinal folds. The patient underwent a 25G vitrectomy and ILM peeling. One week postoperatively OCT imaging indicated glial tissues on the retinal surface which is also easily visible on the color SLO image (blue asterisks). At one month postoperatively, OCT imaging indicated a dissociated optic nerve fiber layer (DONFL) which is also captured with the color SLO image (white arrowheads).

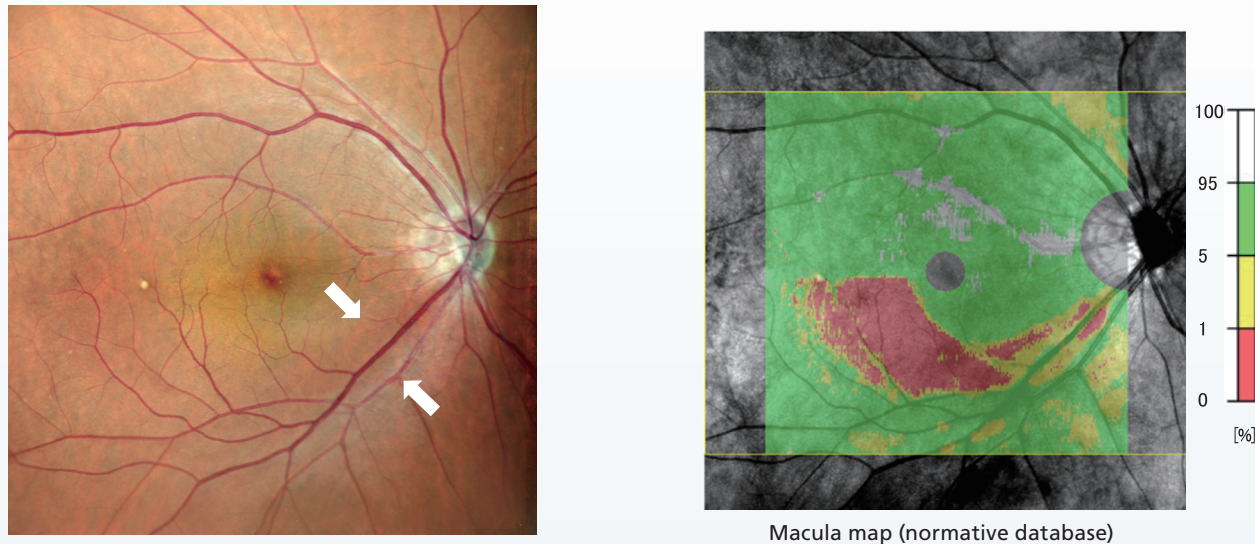




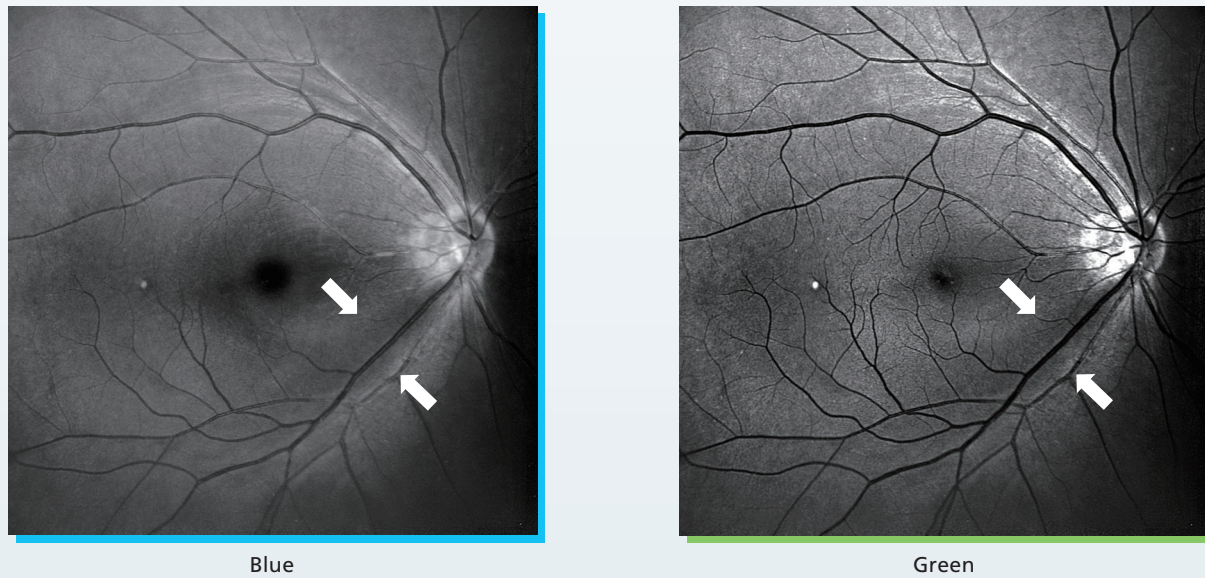
# Early Glaucoma with Retinal Nerve Fiber Layer Defect

**Case 11**  
73-Year-Old Male

Currently, OCT analysis is often used for glaucoma screening, and it is highly effective. However, the detection of retinal nerve fiber layer defects (RNFLD) (white arrows) in myopic eyes must be interpreted with caution due to the influence of factors such as axial length. In such cases, observations using red-free images can be useful for the detection of RNFLD as they provide high-contrast information that is characteristic of the color SLO.

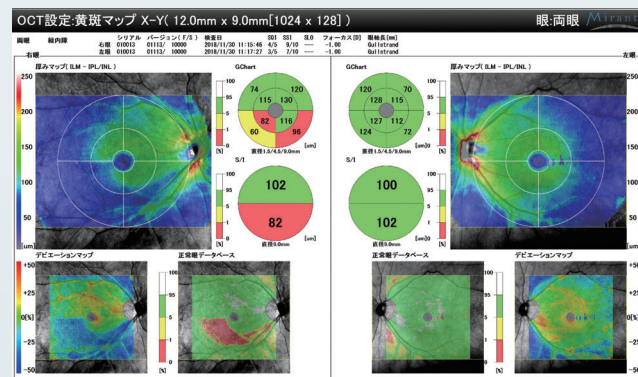


Macula map (normative database)



Blue

Green

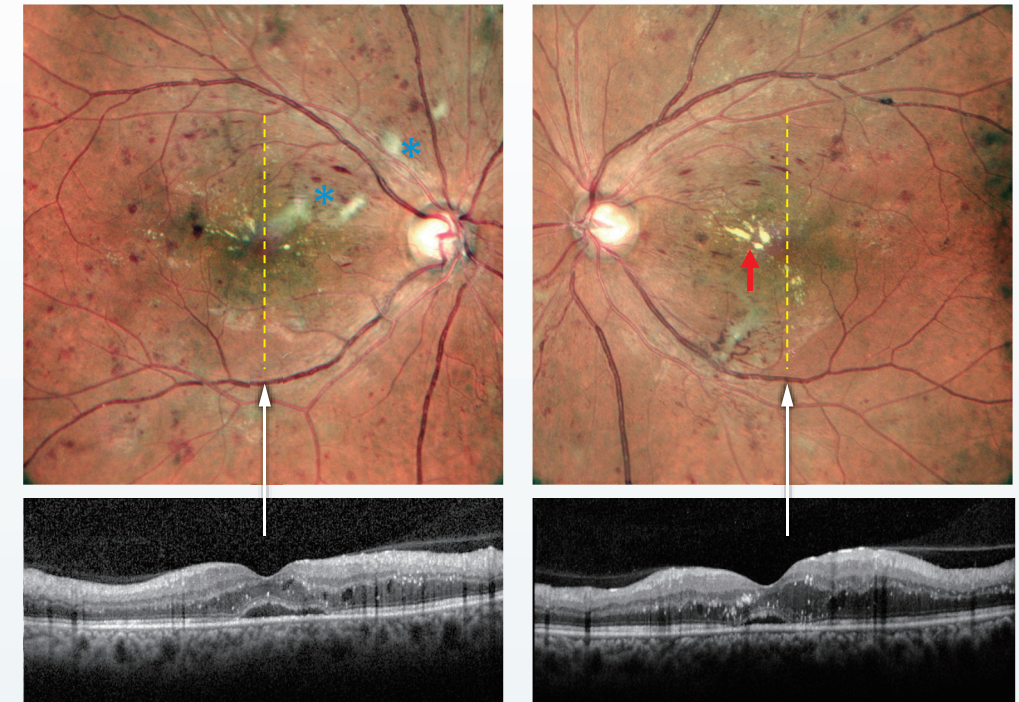


Macula map: Glaucoma analysis (both eyes)

# Diabetic Retinopathy with Dot Hemorrhage and Exudate

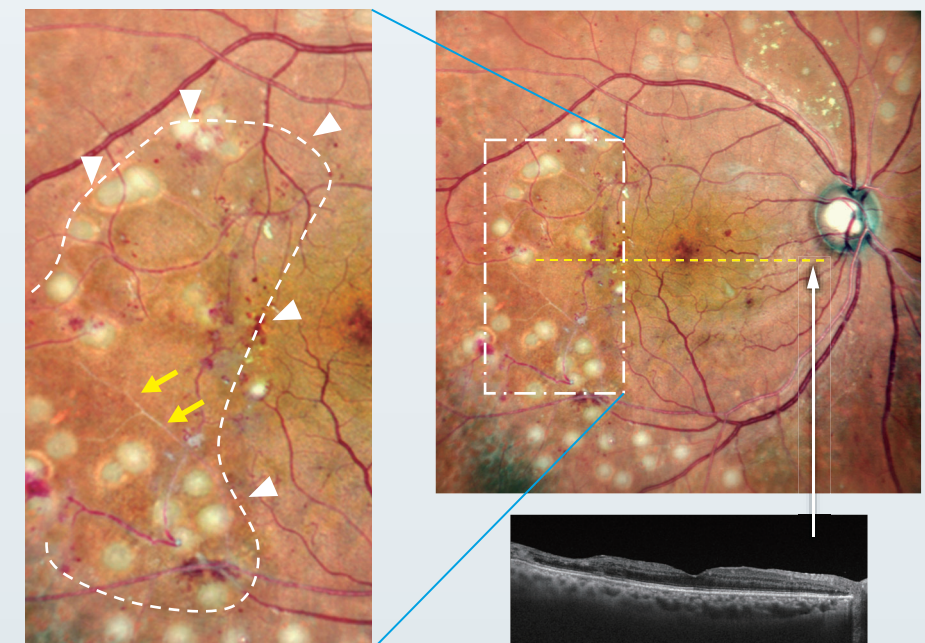
**Case 12**  
41-Year-Old Female

Observations of dot hemorrhage, soft exudate (blue asterisks), and hard exudate (red arrow), are important during fundus examination of diabetic patients. These pathologic features are clearly displayed with the contrast of the color SLO, making it easy to observe the subtle changes. Observation of many cases indicates that the color tone of the color SLO changes to correspond to the OCT findings, making it possible to accurately recognize the changes in the lesion.



**Case 13**  
63-Year-Old Male

A postoperative example of a patient who underwent surgery for vitreous hemorrhage caused by proliferative diabetic retinopathy (PDR). The change in color tone in the SLO image indicates ischemic changes (white arrowheads) of the perfusion area of the inferior vascular arcades, which is consistent with the region of thinning on OCT. Additionally, vascular abnormalities such as whitening of the blood vessels (yellow arrows), are well depicted.



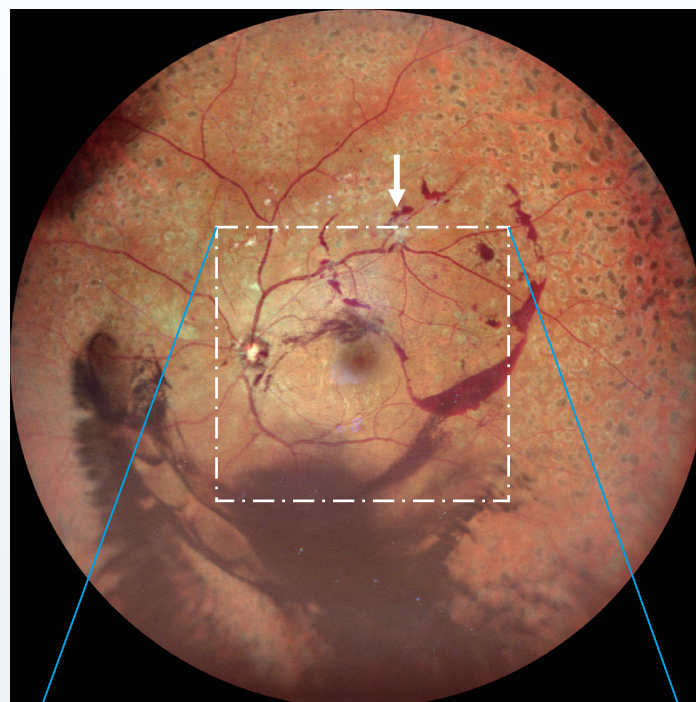

# Vitreous Hemorrhage Associated with Proliferative Diabetic Retinopathy

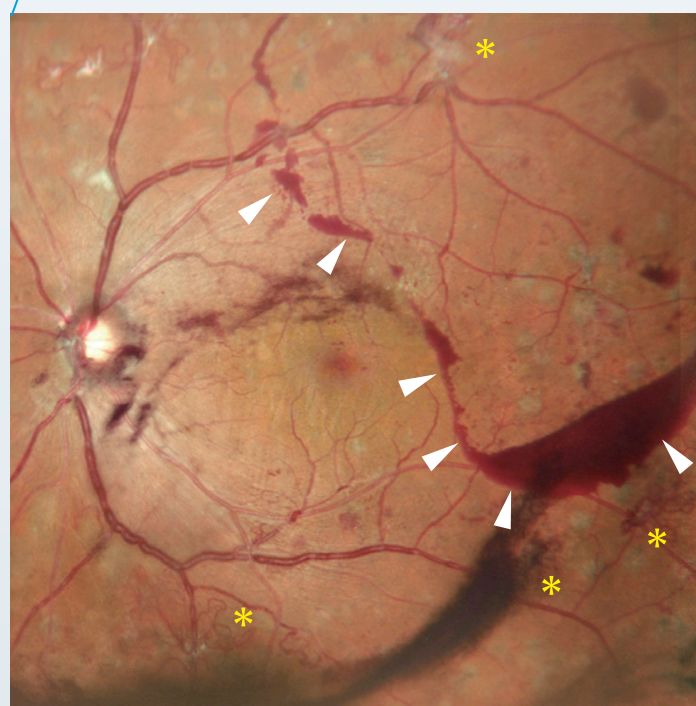
## Case 14

43-Year-Old  
Male

Although panretinal photocoagulation has been performed, the complication of vitreous hemorrhage is observed due to a posterior vitreous detachment (PVD). A proliferative membrane is present above the superior temporal vascular arcade in the widefield 110° (central angle of view 163°) color SLO image. Bleeding that coincides with the border of the vitreous detachment (white arrowheads) and bleeding in the lower vitreous cavity is also visible. The standard 60° (central angle of view 89°) color SLO indicates multiple areas of neovascularization (yellow asterisks) along the vascular arcades. The standard 60° (central angle of view 89°) color SLO and widefield 110° (central angle of view 163°) images are especially effective for assessing various pathologic retinal changes due to diabetes.



Widefield 110° (central angle of view 163°)



Standard 60° (central angle of view 89°)

Panretinal photocoagulation  
scar  
Inferior vitreous hemorrhage

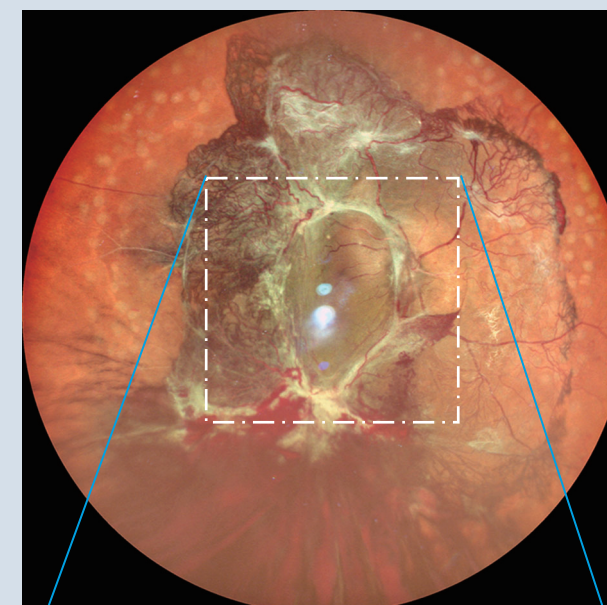
# Proliferative Diabetic Retinopathy

## Case 15

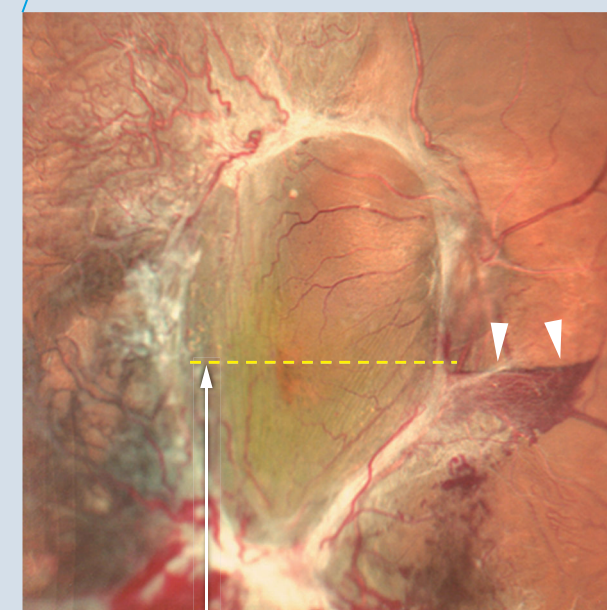
50-Year-Old  
Female

This eye received an intravitreal anti-VEGF injection for diabetic macular edema (DME) secondary to proliferative diabetic retinopathy (PDR). The pretreatment image indicates a proliferative membrane extending from the optic disc to the vascular arcades along with neovascularization. Examination of the macular region indicates tractional retinal detachment due to the proliferative membrane and an underlying hemorrhage around the optic disc (white arrowheads). One week post-anti-VEGF injection, the dramatic effect can be seen including, regression and whitening of neovascular vessels (yellow asterisks).

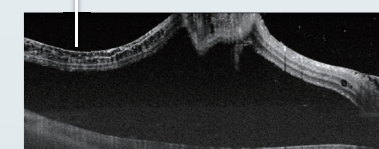
Pretreatment finding



Widefield 110° (central angle of view 163°)

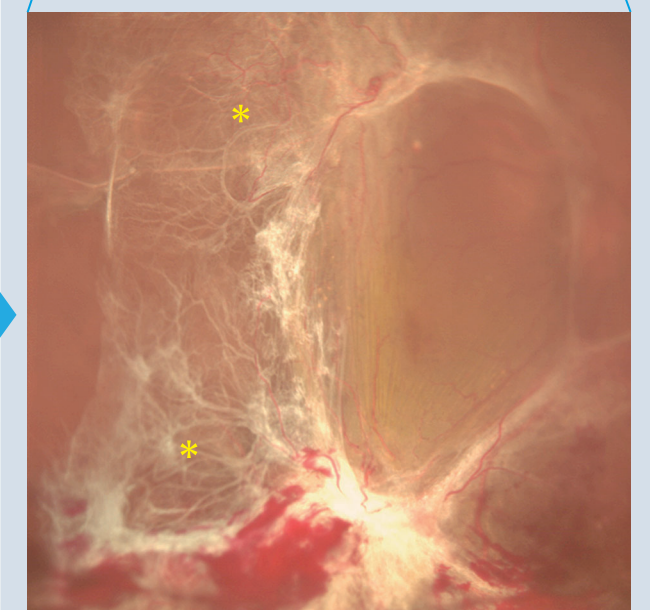
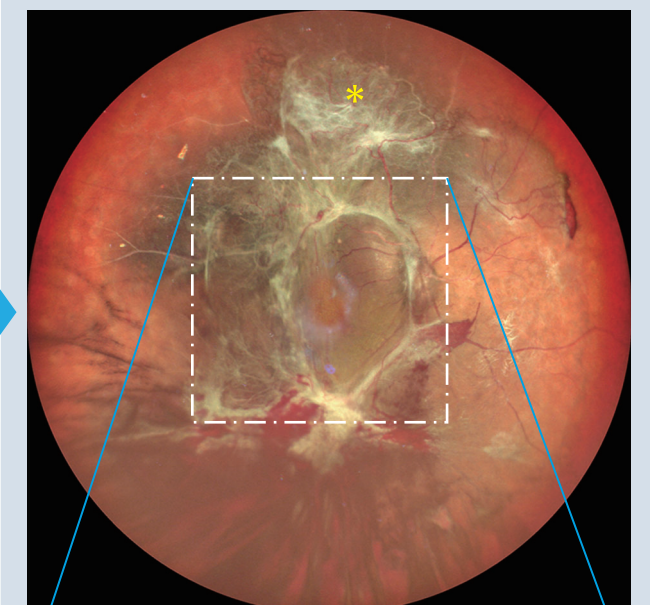


Standard 60° (central angle of view 89°)



Tractional retinal detachment  
with OCT imaging

1 week after anti-VEGF therapy



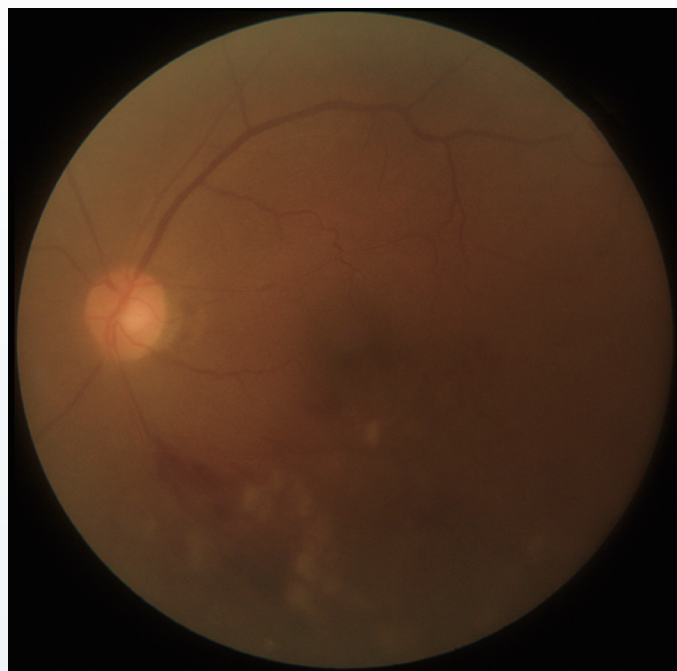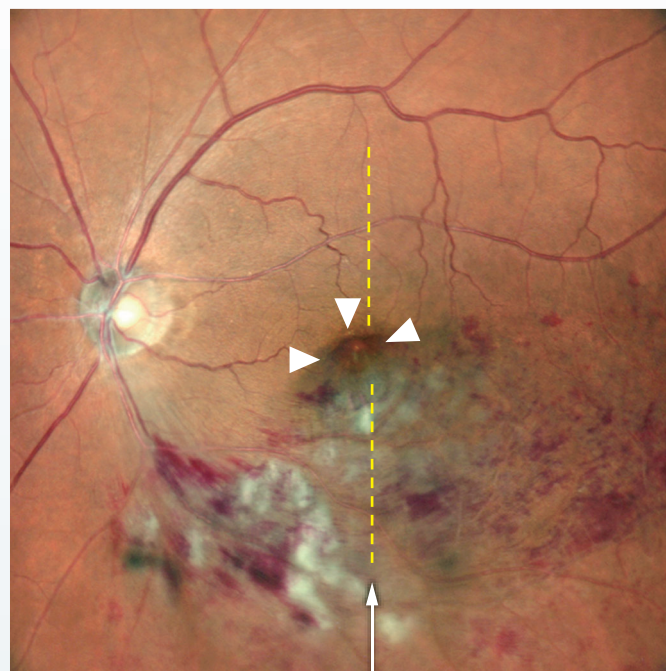


# Retinal Vein Occlusion

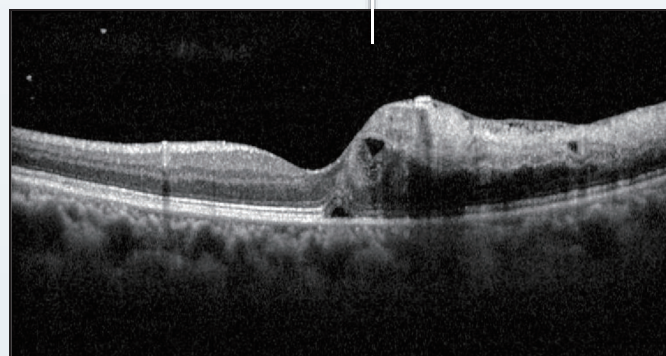
## Case 16

71-Year-Old  
Female

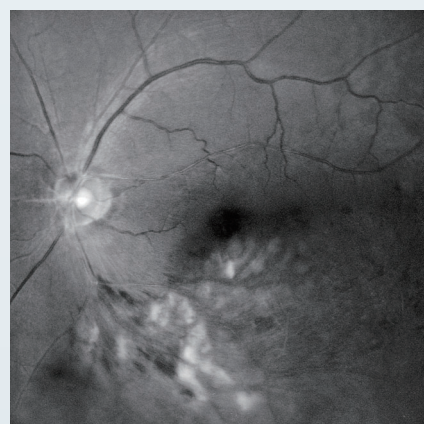In this case of branch retinal vein occlusion (BRVO) in the lower vascular arcades, the color SLO indicates retinal hemorrhage, soft exudates, and small cystic changes in the macula. Comparison of the corresponding fundus camera image shows the remarkable differences in imaging modalities. Small cystic changes in the macula are also visible corresponding to the morphological changes in the OCT image (white arrowheads). The green SLO image most strongly reflects the retinal findings such as blood vessels and bleeding.



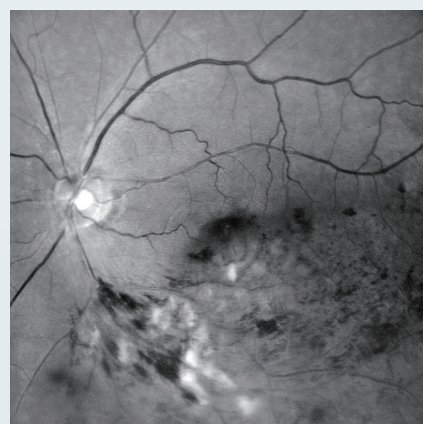
Fundus camera image



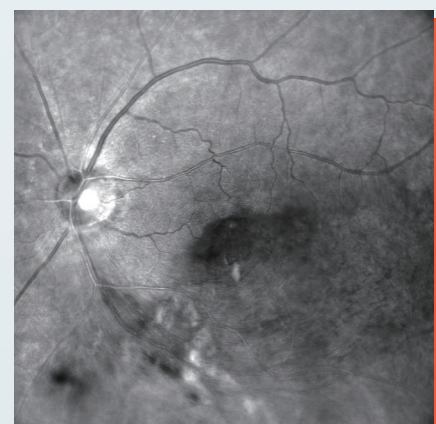
The region of macular edema on OCT is represented by different hues on the color SLO image (white arrowheads).



Blue



Green

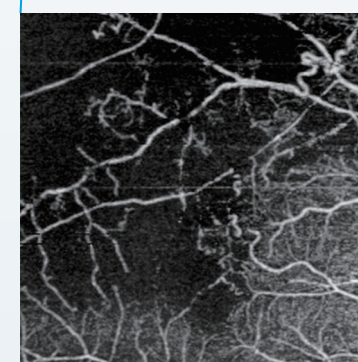
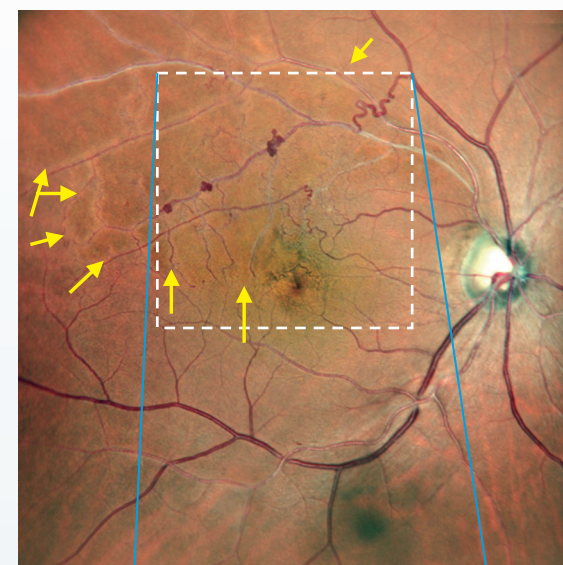


Red

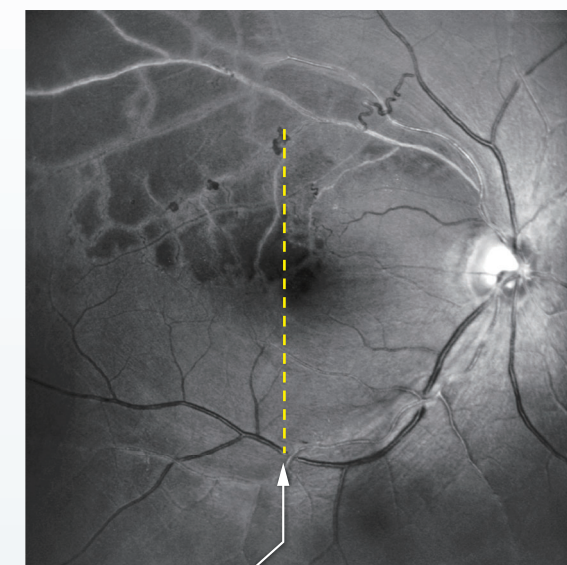
## Case 17

52-Year-Old  
Male

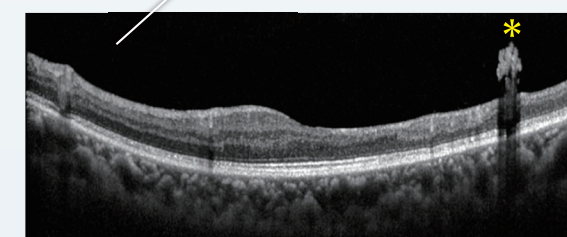
This case of retinal vein occlusion indicates that there is no posterior vitreous detachment (PVD) and the proliferative membrane can be clearly confirmed in the OCT image (yellow asterisk). In addition, the vascular branches cannot be observed because they are in the area where color tone varies on the color SLO image (inside the yellow arrows), but the hypo-reflective area is visible in the blue SLO image. This hypo-reflective area corresponds to the area of non-perfusion on OCT-Angiography and the thinning region on the OCT image due to structural retinal damage.



OCT-Angiography



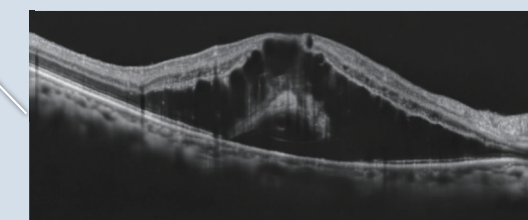
Blue



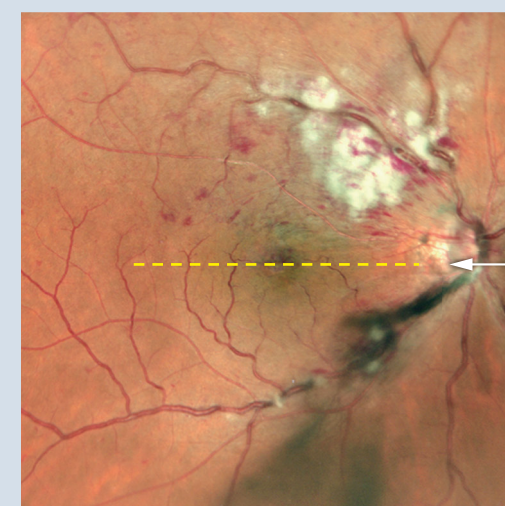
## RVO Additional Case

57-Year-Old  
Male

Soft exudates in the upper vascular arcades, blood vessel disruption, bleeding from the surface of the retina can be confirmed. The greenish aspect of the macula is suspected to be macular edema.



OCT showed edematous changes in the macula.

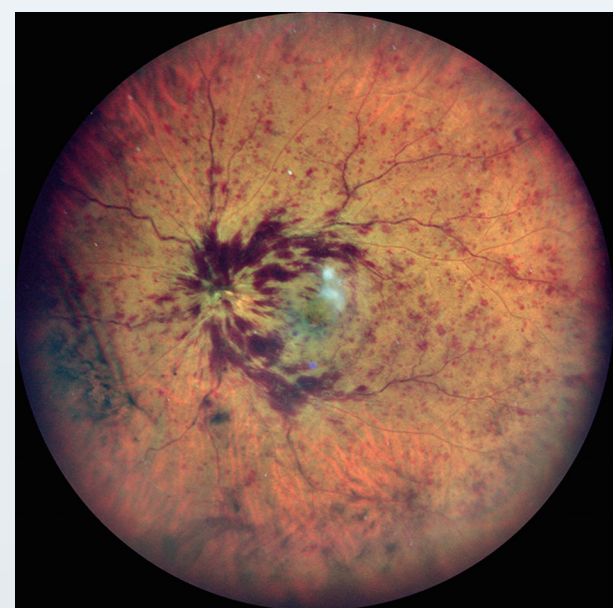
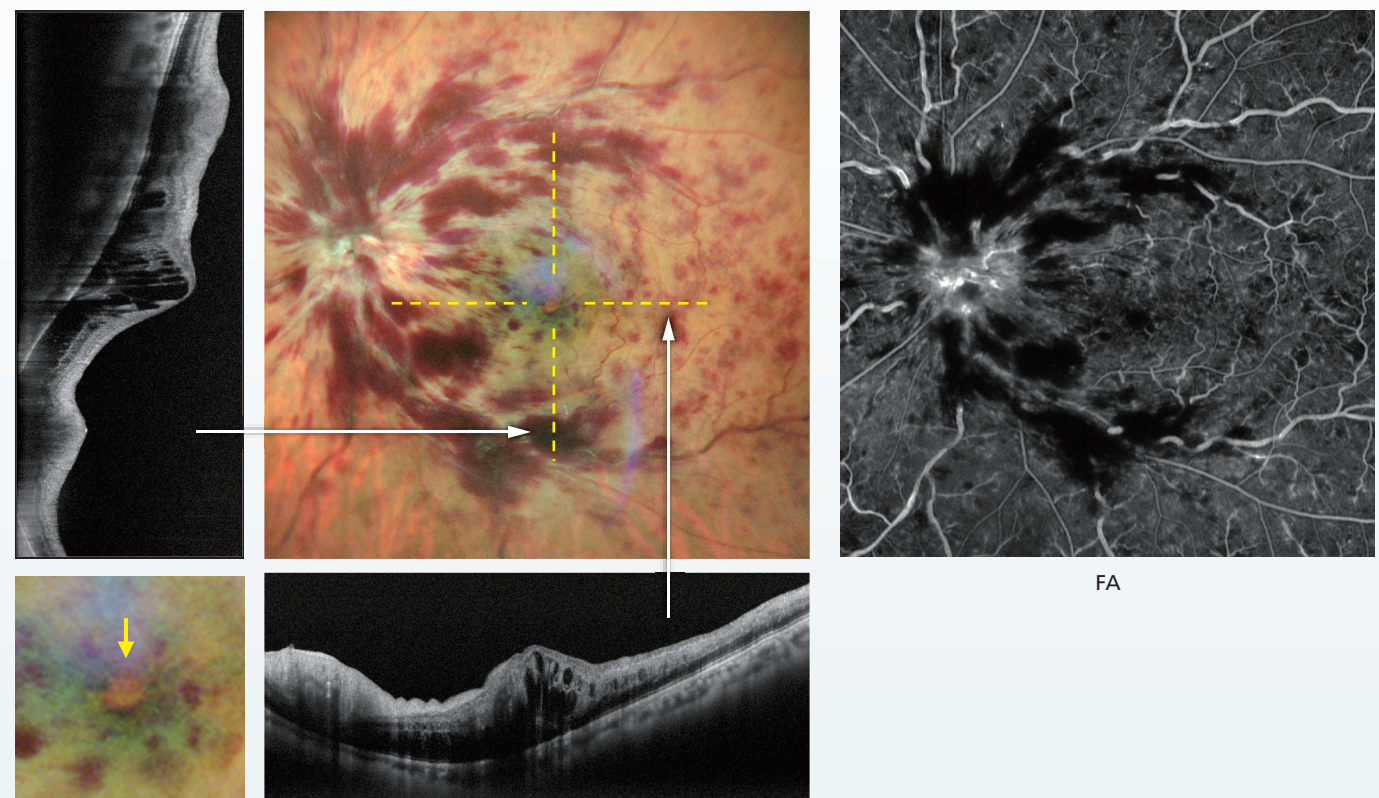




# Central Retinal Vein Occlusion

**Case 18** 50-Year-Old Male

Bleeding around the optic disc and flame-shaped hemorrhage can be observed with the color SLO. Fluorescein angiography (FA) clearly shows the blood vessels, confirming that the ischemic area is not widespread. This case is characterized by the cystic edema (yellow arrow) associated with central retinal vein occlusion (CRVO) in the macula imaged with color SLO.



**CRVO  
Additional  
Case**

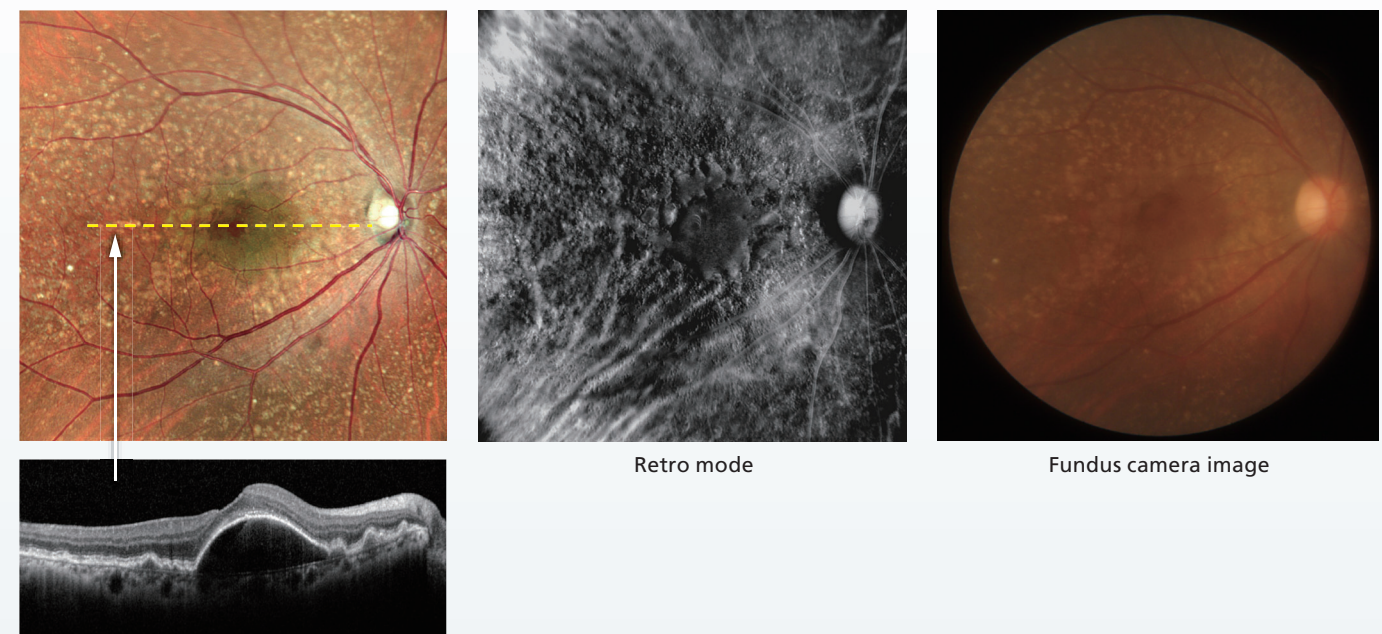
81-Year-Old Male

Soft exudates (white punctate changes), macular edema associated with CRVO, and retinal hemorrhage are clearly visible on the images.

# Early Age-Related Macular Degeneration

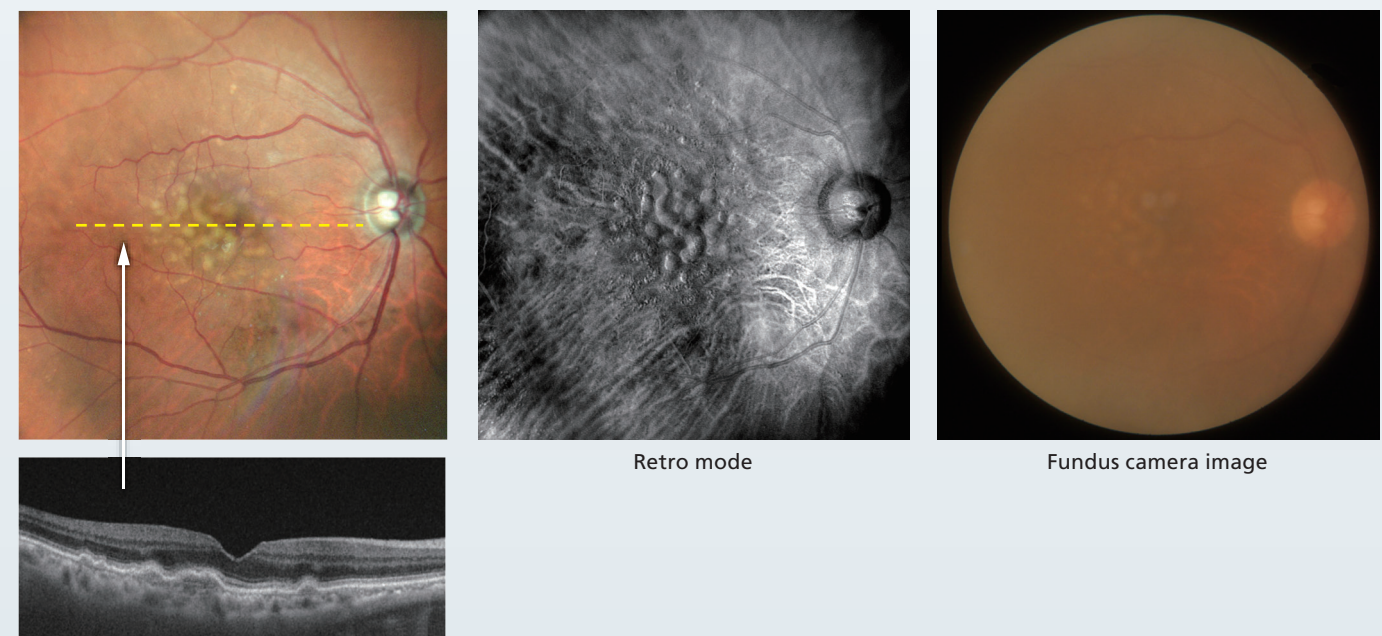
**Case 19** 66-Year-Old Female

Drusen are an important early sign of age-related macular degeneration (AMD). A detailed imaging study is crucial because the morphology changes over time, and the color SLO facilitates easy assessment of the structure and spread of drusen. In this case there is a large pigment epithelial detachment (PED) in the macular region, which appears greenish-red on the color SLO image. Additionally, Retro mode, a unique imaging modality of the Mirante, confirms the irregular nature of drusen and PED in the retinal pigment epithelial cell (RPE) layer.



**Case 20** 69-Year-Old Male

Color SLO enables a well-defined finding of soft drusen, with a significant difference compared to the fundus camera image. In Retro mode imaging, fusion of the soft drusen can be observed.





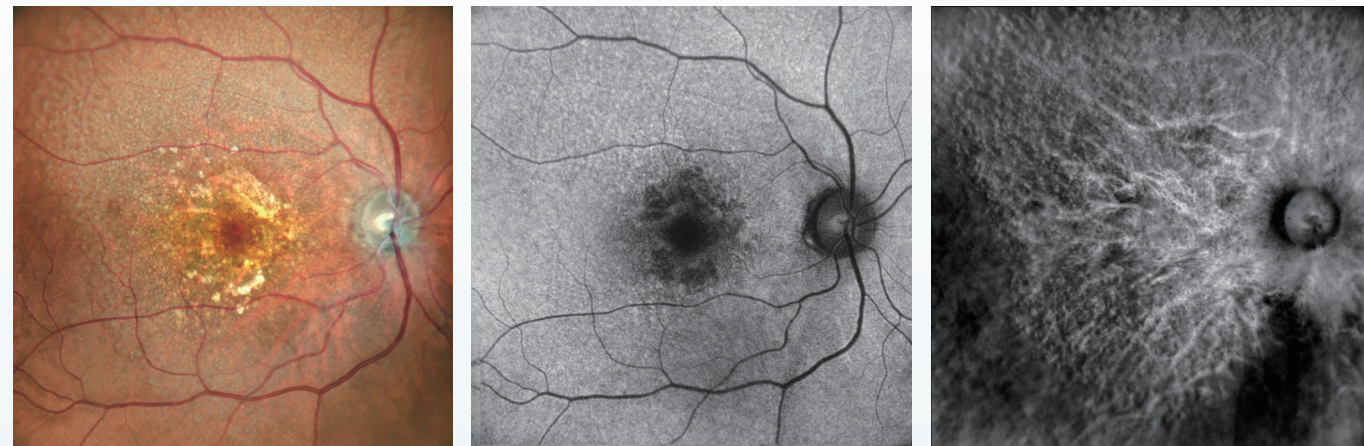


## Atrophic Age-Related Macular Degeneration

### Case 21

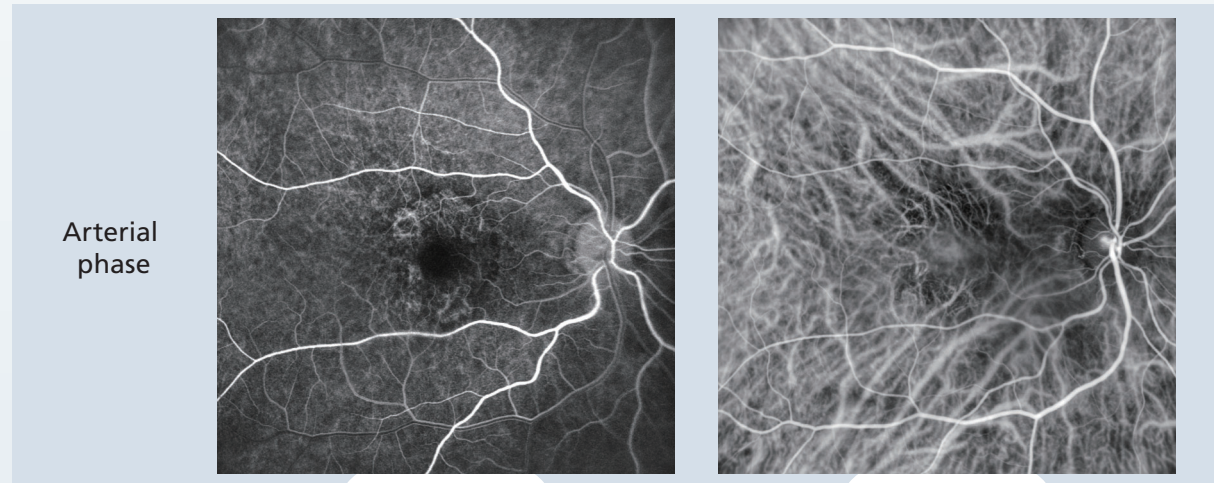
73-Year-Old  
Female

Color SLO imaging indicates a region with abnormal retinal pigment epithelial (RPE) cells centered on the macula indicated as an area with color tone variation in the posterior pole. Fundus autofluorescence (FAF) shows as a hypo-fluorescent region. Additionally, reticular pseudodrusen are confirmed in a wide area of the posterior fundus and are visible as small uneven areas in Retro mode imaging. Indocyanine green angiography (ICG) also shows this change with well-defined contrast imaging. Blood vessels are clearly depicted from both FA and ICG images in the early phase of contrast enhancement, and a window defect is present. Abnormal staining can be confirmed mainly in the atrophic lesion. ICG shows choroidal blood vessels in high contrast allowing detailed evaluation of choroidal blood flow.



Blue-FAF

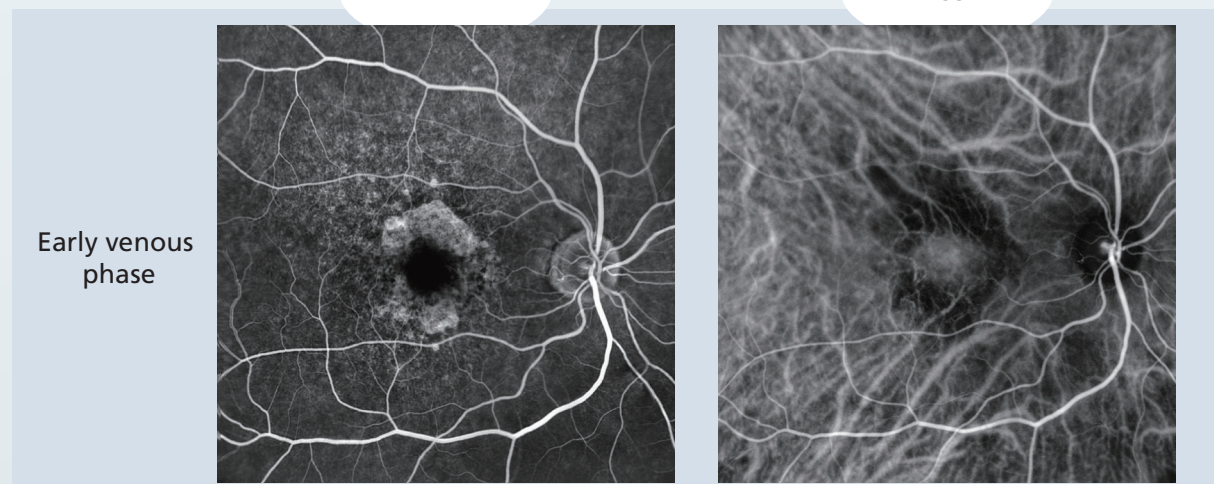
Retro mode



Arterial  
phase

FA

ICG



Early venous  
phase

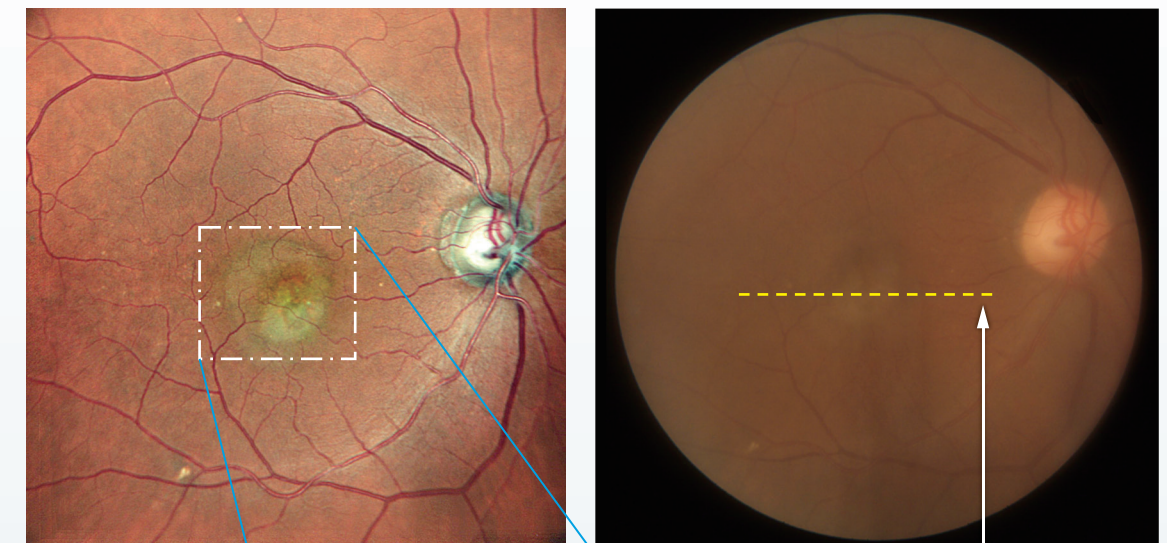


## Exudative Age-Related Macular Degeneration

### Case 22

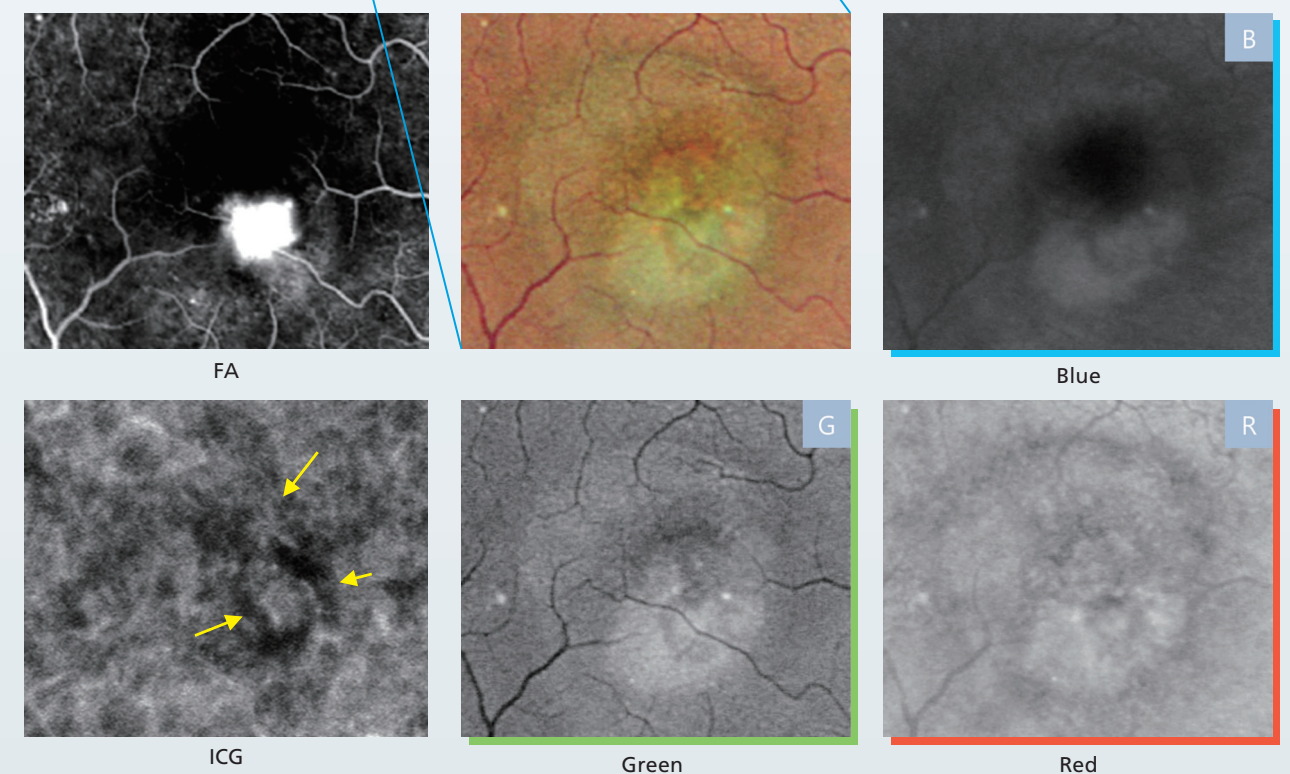
72-Year-Old  
Male

The structural changes in OCT are clearly depicted on the color SLO as white-toned choroidal neovascularization (CNV) and serous retinal detachment mainly in the macula. Fluorescein angiography (FA) confirms type II CNV showing vigorous exposure, and ICG also indicates CNV (yellow arrows). The SLO images for each wavelength in this case of age-related macular degeneration (AMD), indicate the center of the lesion is located in the RPE and choroid, and the image with the red wavelength has the highest contrast.



Fundus camera image

CNV and subretinal  
exudate are present  
on the OCT image.



FA

Blue

B

ICG

Green

G

Red

R



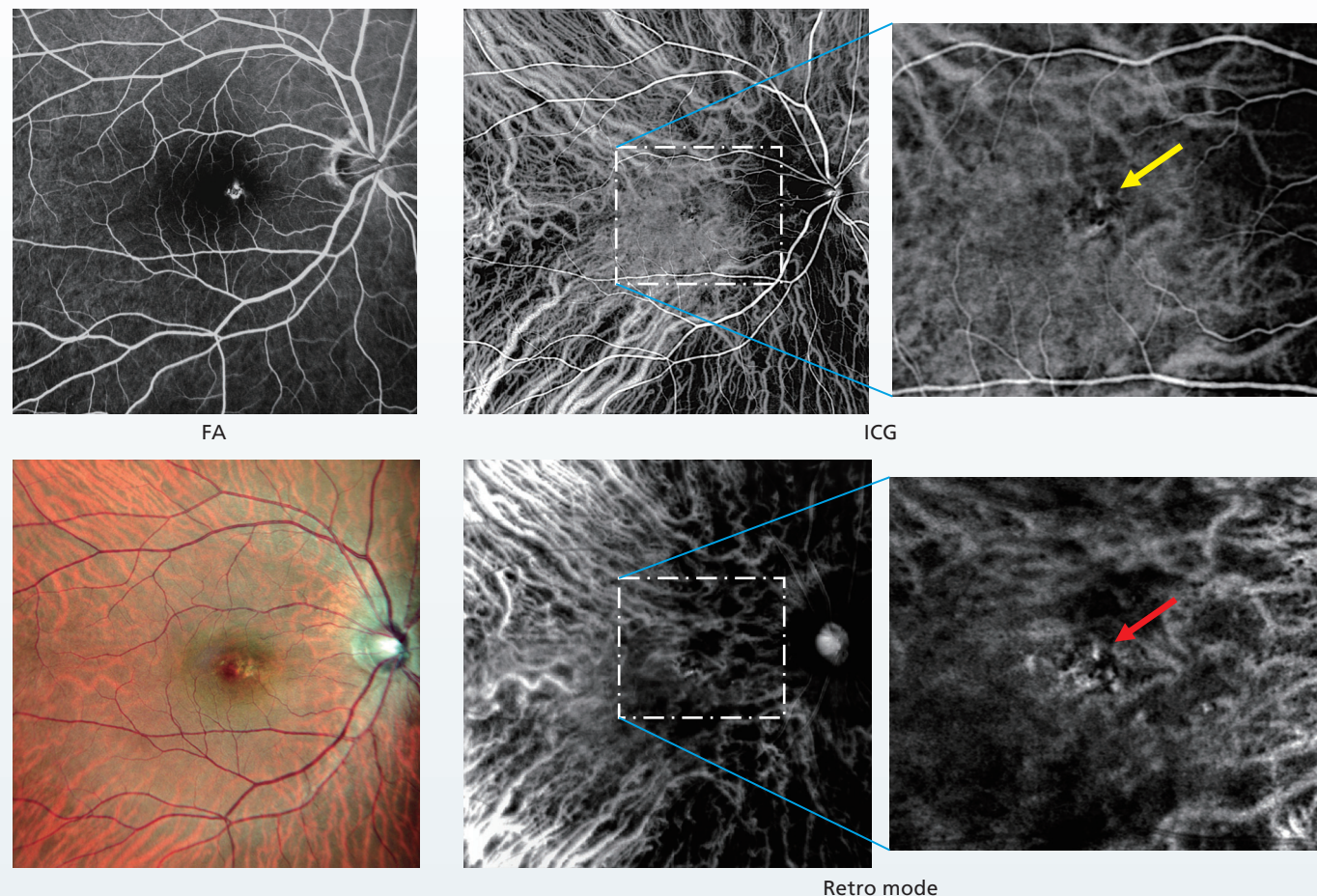


## Exudative Age-Related Macular Degeneration

### Case 23

53-Year-Old  
Female

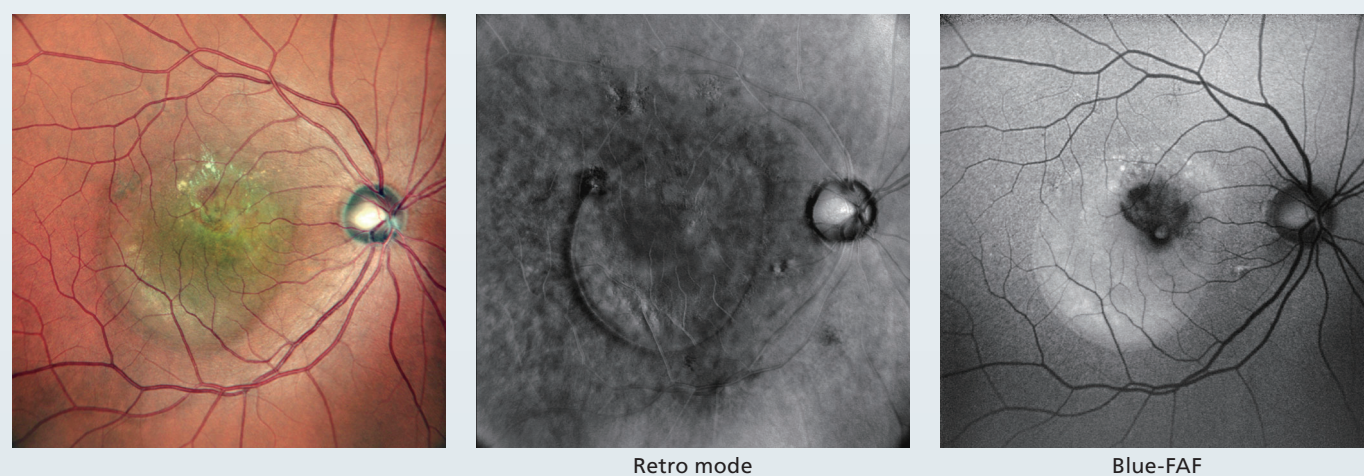
SLO fundus image shows an area with a different color tone nasal to the fovea, which is consistent with the hyper-fluorescent region without leakage on the fluorescein angiography (FA). ICG clearly shows the choroidal blood vessels and magnification of the early-stage image shows extremely small choroidal neovascularization (CNV)-like structures (yellow arrow). A blood vessel-like structure (red arrow) different from the surrounding area is confirmed in the same location with Retro mode imaging. An example of a case where a small CNV can be detected by high-definition contrast enhancement.



### Case 24

65-Year-Old Male

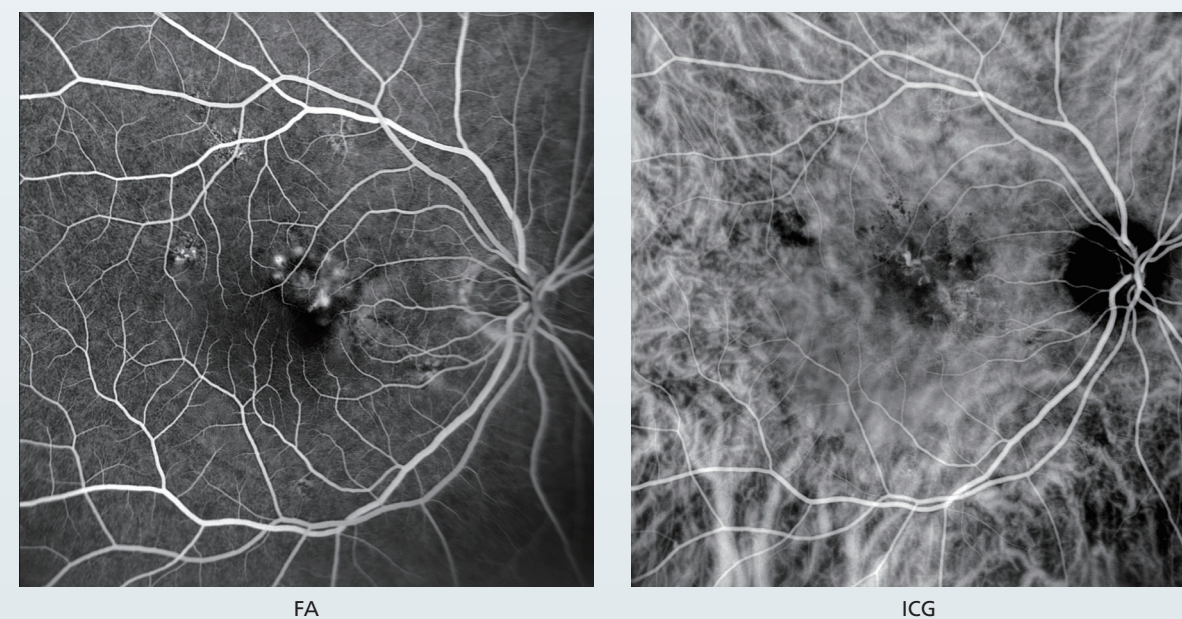
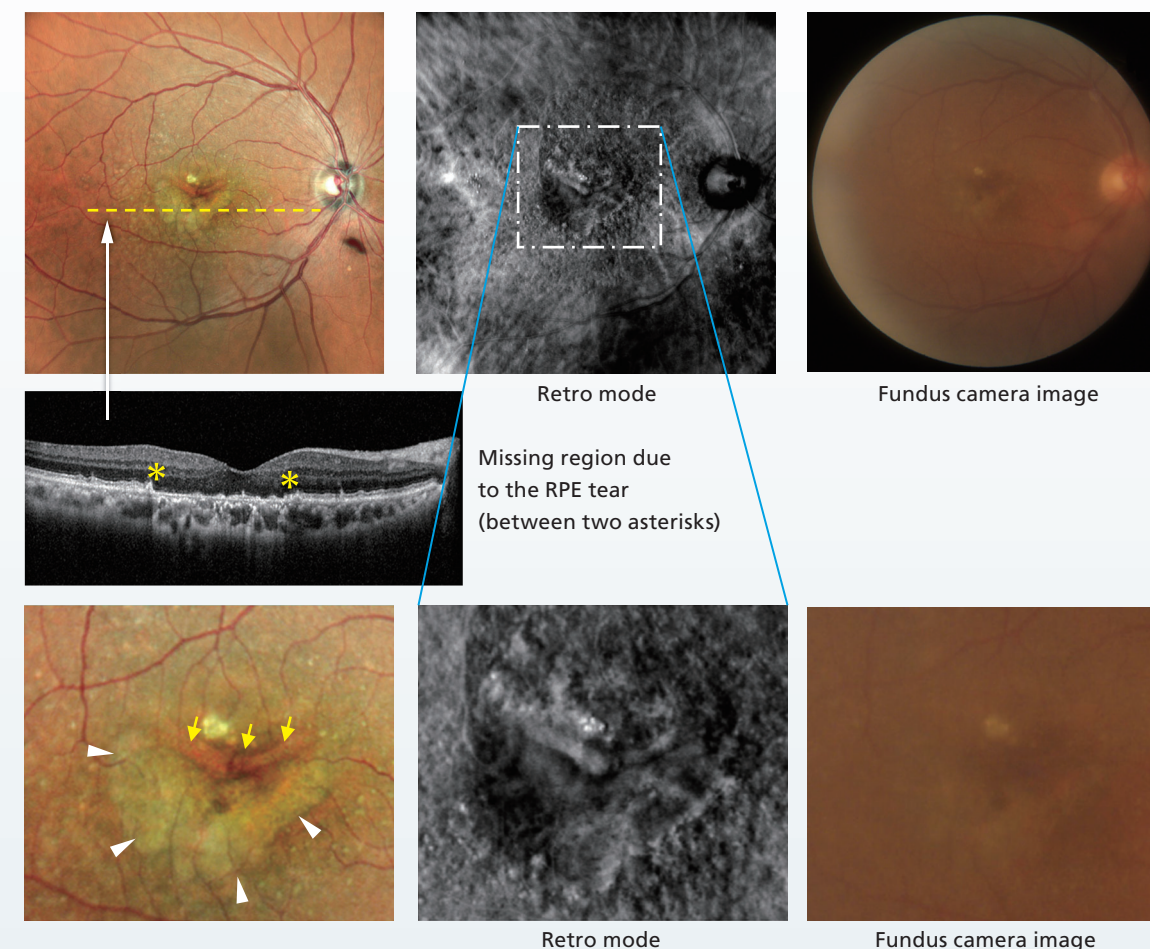
Changes associated with exudative age-related macular degeneration (AMD) near the retinal pigment epithelial (RPE) cells are visible by color SLO and Retro mode imaging. RPE abnormalities at the border of the serous retinal detachment are also visible. On fundus autofluorescence (FAF), serous retinal detachment appears as a hyper-fluorescent region, and CNV was confirmed in this case.



### Case 25

78-Year-Old  
Male

The CNV just below the macula was accompanied with a large pigment epithelial detachment (PED), but a complication of retinal pigment epithelial (RPE) tear was newly observed during the progression of this case. Color SLO shows a folded RPE (yellow arrows) and crescent-shaped atrophy below it (white arrowheads). The uneven changes can also be observed in Retro mode imaging. Reticular pseudodrusen is also present in the posterior pole indicating the potential for future deterioration.



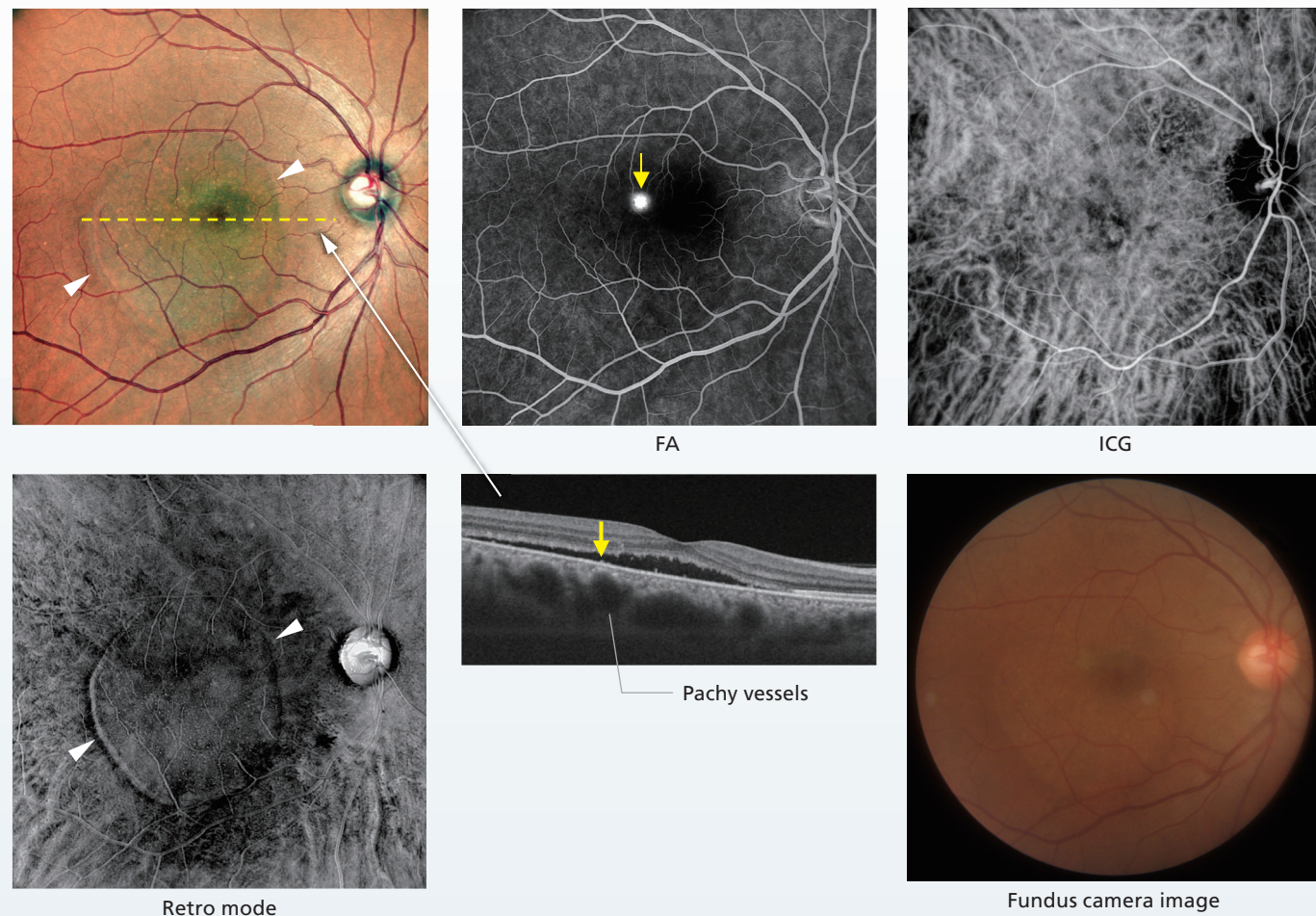


# Exudative Age-Related Macular Degeneration (Associated with Pachychoroid)

## Case 26

48-Year-Old  
Male

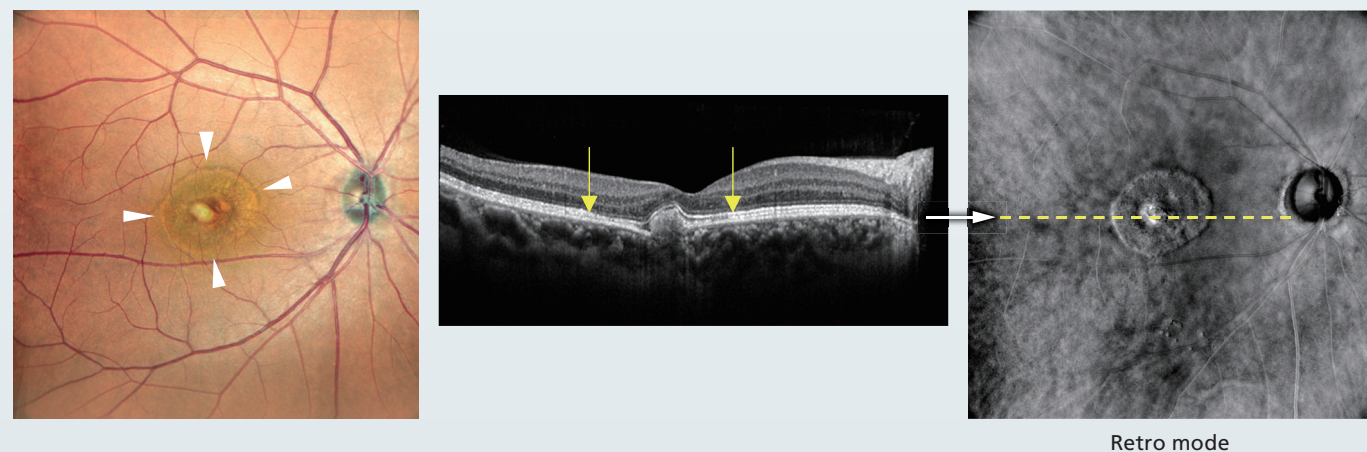
In this case of central serous chorioretinopathy, the extent of serous detachment is clearly presented with color SLO and Retro mode imaging (white arrowheads). Fluorescein angiography (FA) confirmed a burst-type leakage, and ICG shows the vasodilation of Haller's layer in the choroid. The leakage shown on FA (yellow arrows) coincides with the dilated vessels (pachy vessels) above.



## Case 27

51-Year-Old  
Female

This case of focal choroidal excavation (FCE) confirms a whitish area indicating choroidal neovascularization (CNV) on the temporal aspect of the macula. In addition, the boundary (yellow arrows) of the abnormal region of the ellipsoid zone (EZ) on OCT is observed as a ring-shaped clear line (white arrowheads) with color SLO and as a ring on Retro mode imaging.

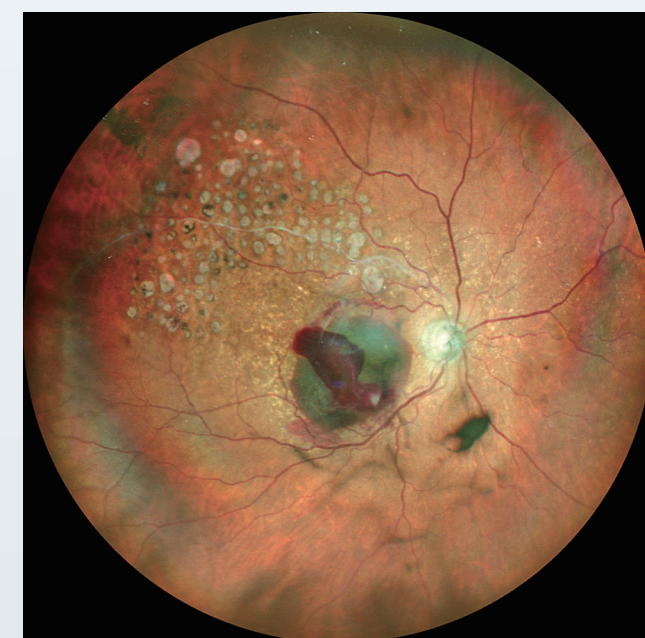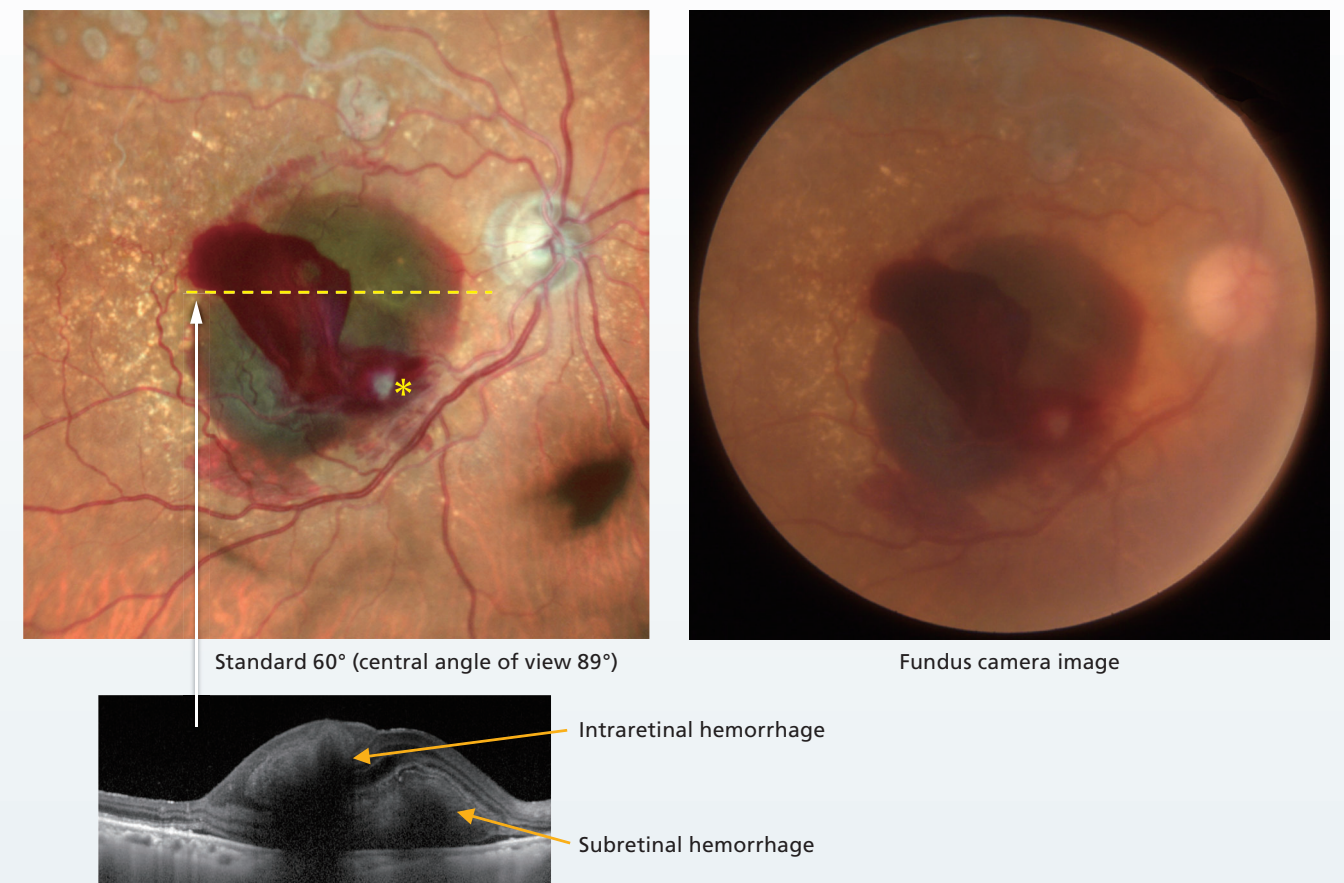


# Retinal Microaneurysm Rupture

## Case 28

90-Year-Old  
Female

Intraretinal and subretinal bleeding due to retinal microaneurysm rupture are confirmed, with the standard 60° (central angle of view 89°) color SLO showing different color tones based on the depth of the blood. The red and green colors represent intraretinal and subretinal hemorrhages respectively, and the color changes correlate with OCT. Retinal microaneurysm is confirmed as a white circular lesion (yellow asterisk) inferior to the macula. In addition, a history of retinal vein occlusion and retinal photocoagulation treatment is confirmed by evaluating the vascular arcades.



Widefield 110° (central angle of view 163°)

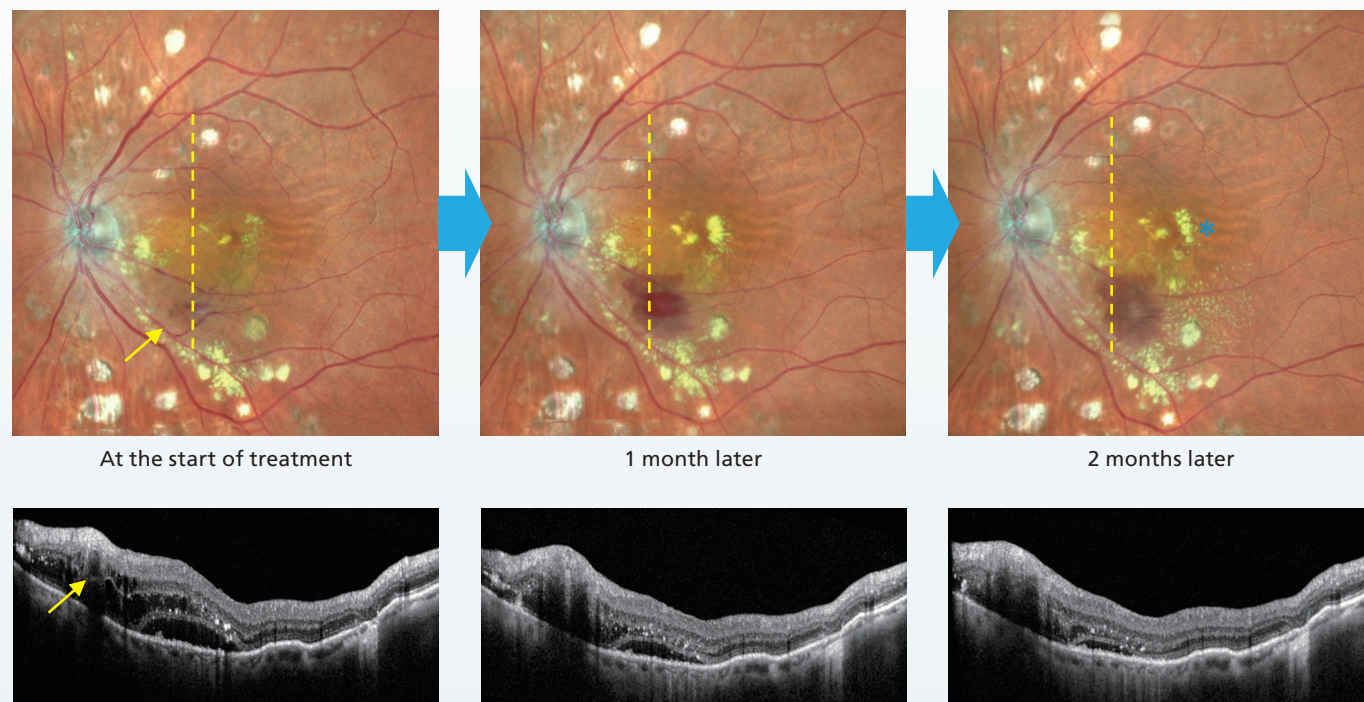


## Observation of Changes over Time: Retinal Microaneurysm Rupture

### Case 29

83-Year-Old  
Female

This patient with hypertension underwent retinal photocoagulation elsewhere for complications with retinal vein occlusion. However, retinal microaneurysm rupture occurred despite a good temporary outcome post-laser photocoagulation. At the initial visit, retinal microaneurysm (yellow arrows), retinal hemorrhage, hard exudate, and serous retinal detachment were observed in the lower vascular arcades. The patient was managed conservatively, but with enlargement of the hard exudate, photocoagulation was performed directly on the microaneurysm. After treatment, the changes over time can be clearly observed. Although bleeding increased after the treatment, the aneurysm shrunk, and serous retinal detachment partially resolved and hard exudates (blue asterisk) decreased as confirmed by OCT.

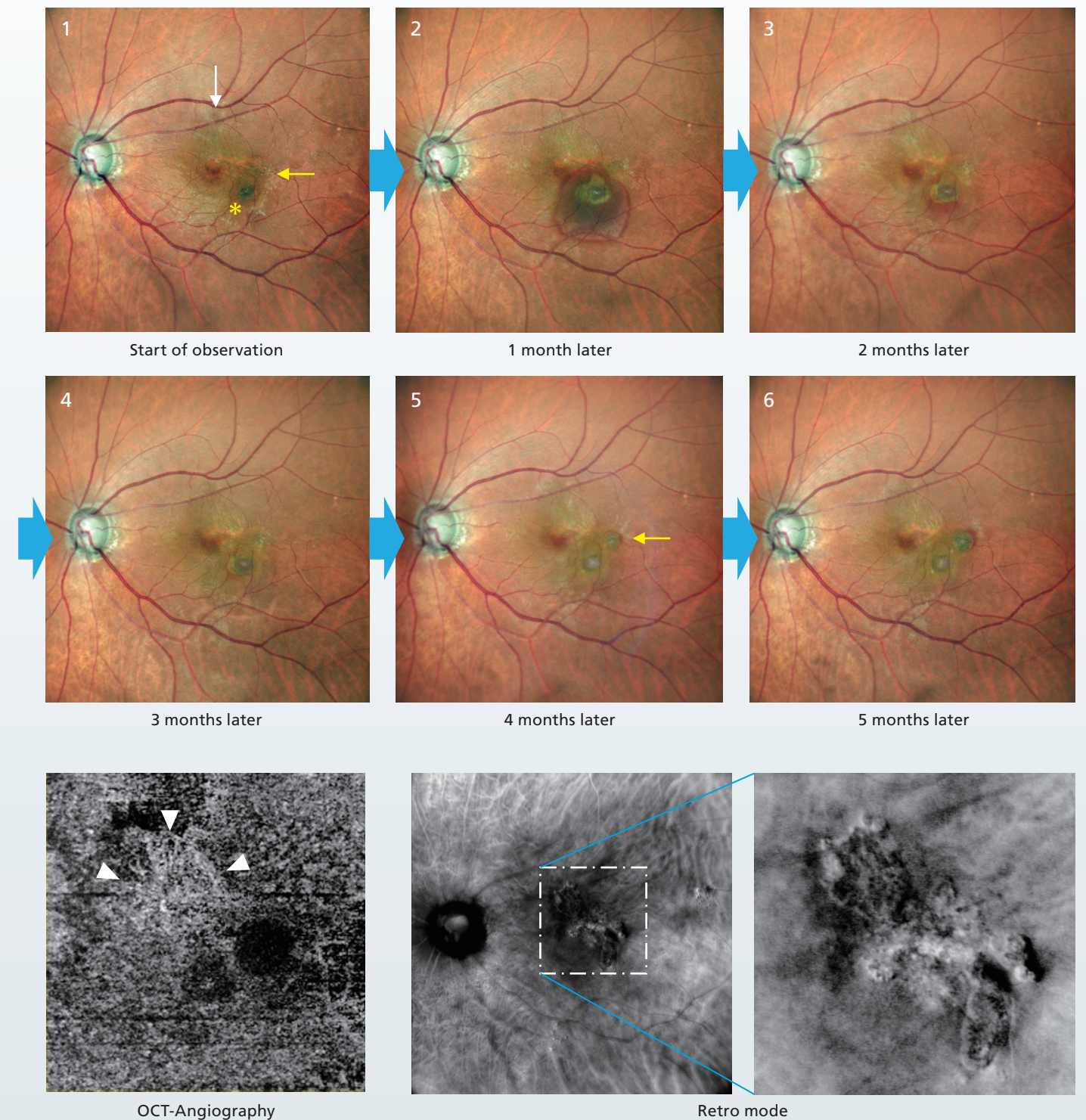


## Observation of Changes over Time: Polypoidal Choroidal Vasculopathy

### Case 30

82-Years-Old  
Male

This case of polypoidal choroidal vasculopathy (PCV) was managed with anti-VEGF therapy; however, activity increased rapidly during the 5 months follow-up and, there was marked choroidal neovascularization (CNV) and accompanying changes. There is a polyp that initially bled on the inferotemporal side of the macula (yellow asterisk). Color SLO imaging shows the extent of the bleeding and the shape of the polyp. Additionally, the small original polyp (yellow arrows) expanded rapidly and was bleeding at 4 months follow up. An extremely small polyp is present along the superior vascular arcades (white arrow). CNV was confirmed with OCT-Angiography in the center of each polyp including the macula (white arrowheads), and the shape of CNV is also well depicted by Retro mode imaging.



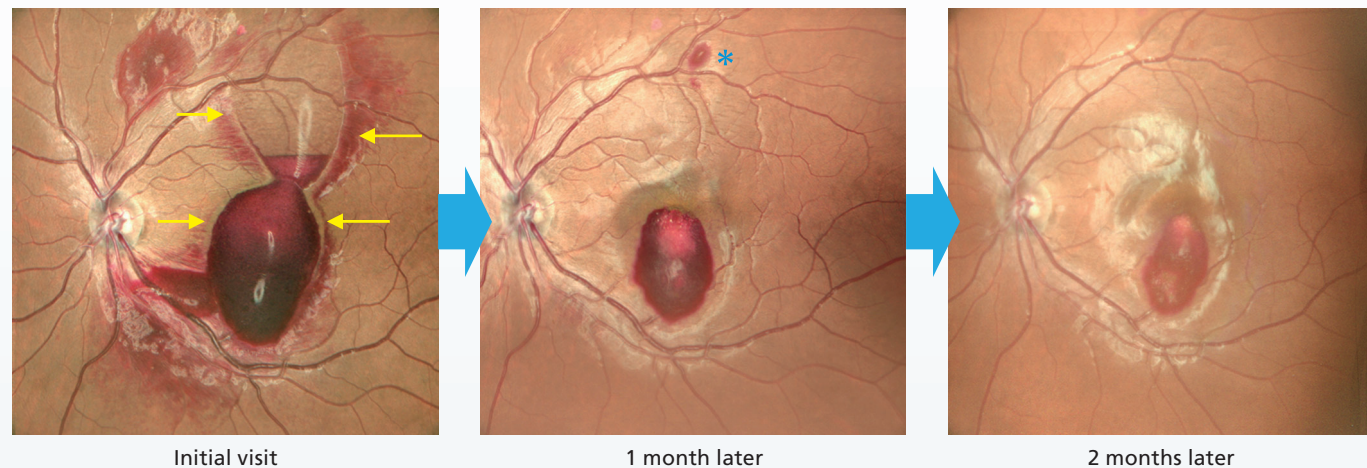


# Observation of Changes over Time: Leukemic Retinopathy, Cat-Scratch Disease

## Case 31

39-Year-Old  
Male

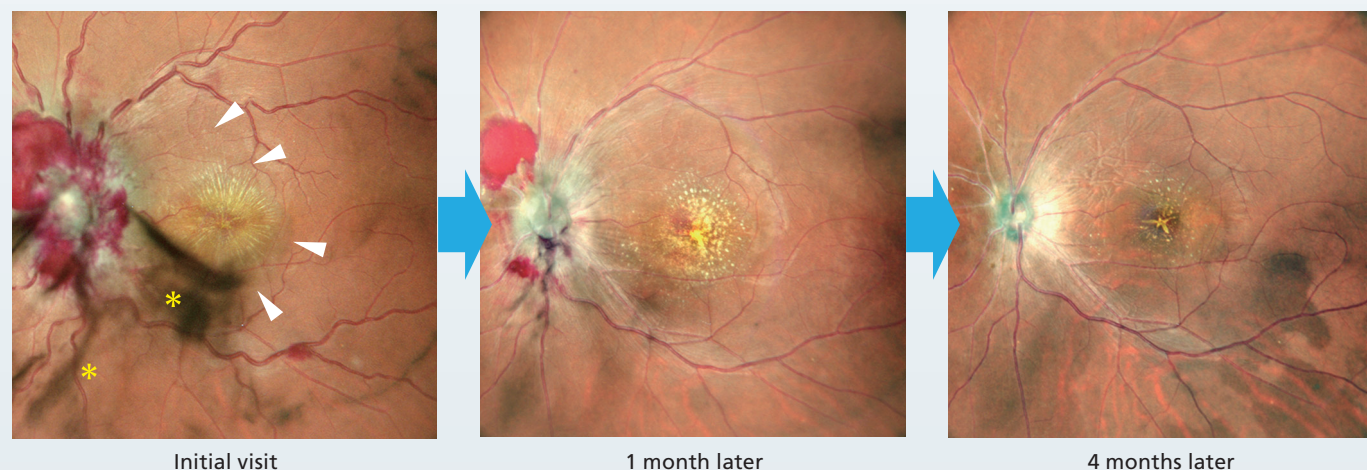
In this case of leukemic retinopathy, the extent and shape of the retinal hemorrhage are clearly depicted with color SLO imaging. At the presenting visit, bleeding under the internal limiting membrane (ILM) (yellow arrows) and nival formation were confirmed, and a characteristic white change in the center of the region of the blood was also present. The changes in bleeding over time and the appearance of new bleeding (blue asterisk) are clearly imaged with color SLO.



## Case 32

43-Year-Old  
Male

This case presents the change in cat-scratch disease over time. Color SLO at the initial visit indicated bleeding centered on the optic disc, dilated blood vessels, retinal detachment at the optic disc and macula (white arrowheads), a star-shaped hard exudate on the macula, and vitreous opacity (yellow asterisks). Imaging shows the improvement in the pathologic features over time.

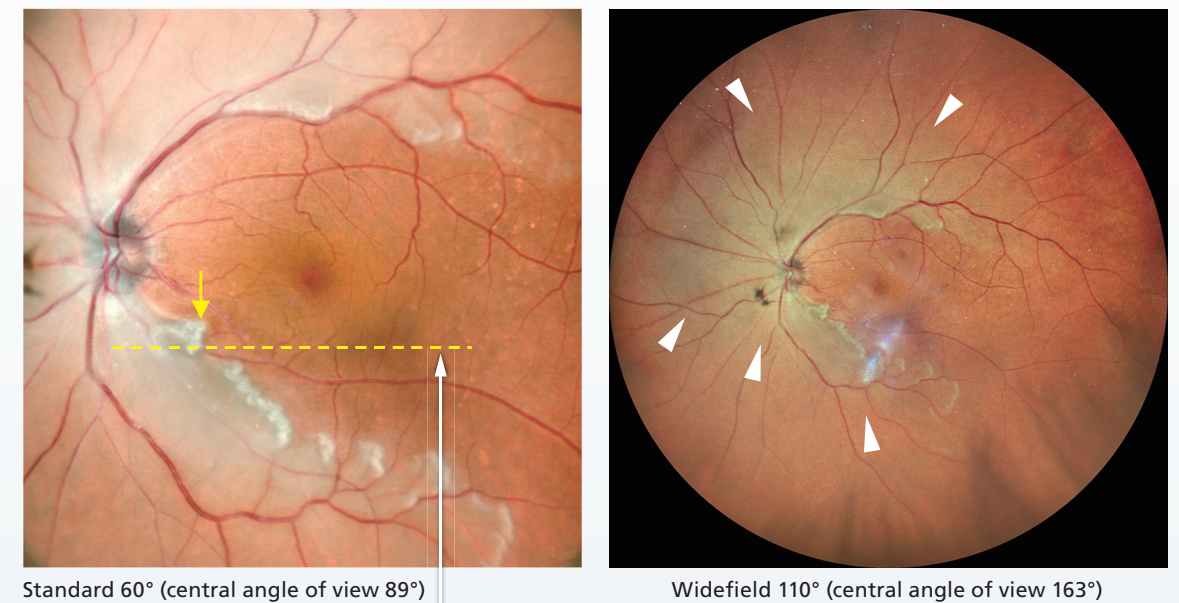


# Central Retinal Artery Occlusion

## Case 33

81-Year-Old  
Female

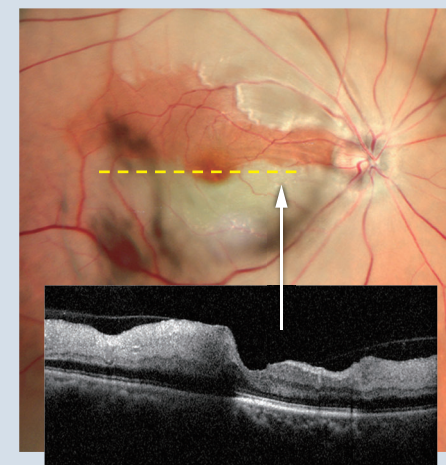
The region of retinal ischemia associated with central retinal artery occlusion (CRAO) is represented in white with standard 60° (central angle of view 89°) color SLO, which is clearly different from the normal site. Changes in color tone correspond to structural OCT changes (yellow arrows), indicating macular sparing in this case. Widefield 110° (central angle of view 163°) color SLO allows assessment of the entire lesion (white arrowheads).



## CRAO Additional Case

72-Year-Old Male

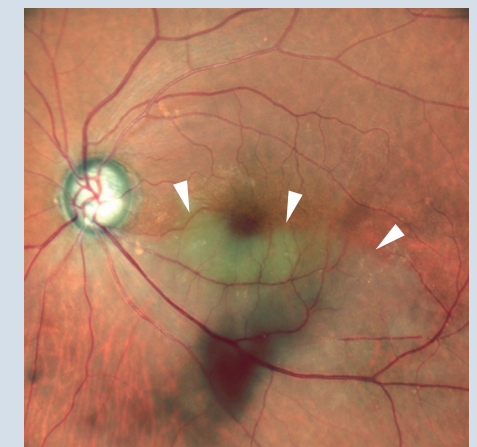The occluded and normal areas are clearly depicted with the variation in color of the SLO image, corresponding to the morphological changes on OCT.



## CRAO Additional Case

82-Year-Old Male

Vascular disruption and elevated areas are clearly imaged in this case of inferior hemispheric retinal artery occlusion (hemi-RAO).

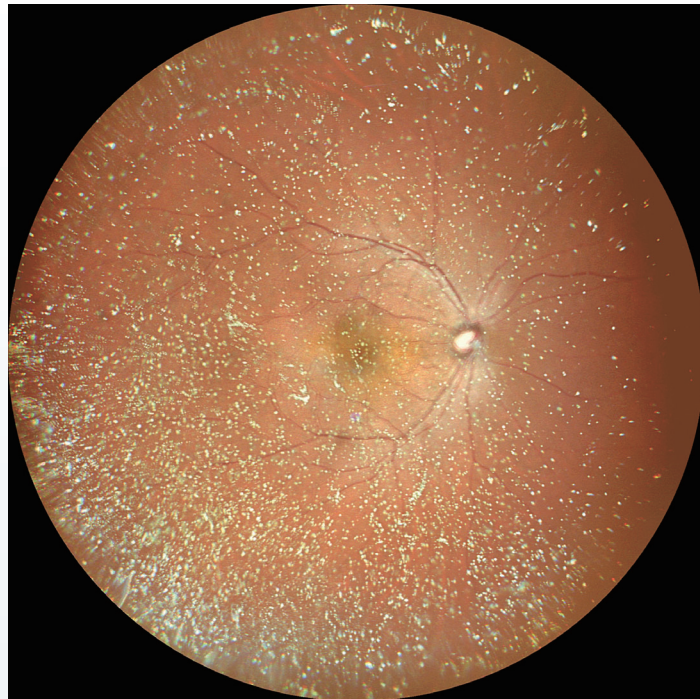




# Asteroid Hyalosis

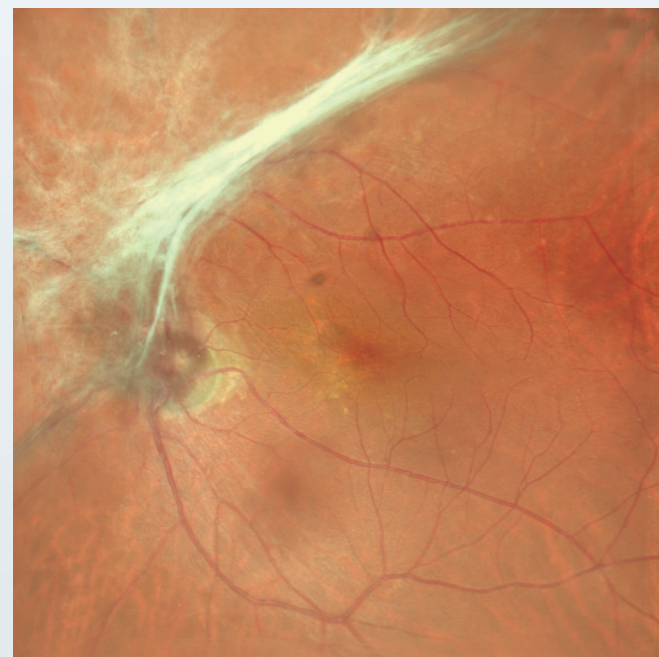Case 34 Widefield 110° (central angle of view 163°) color SLO enables simultaneous observation of fundus and vitreous opacity due to asteroid hyalosis.

72-Year-Old Male

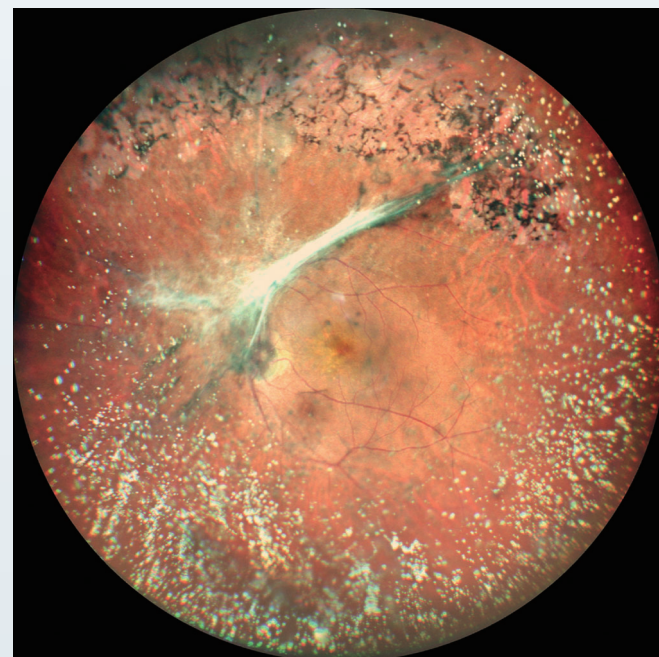


Case 35 This is a case of proliferative changes of the optic disc and asteroid hyalosis as complications of obsolete retinal vein occlusion (RVO). The morphology of the proliferative membrane can be observed with standard 60° (central angle of view 89°) color SLO. In addition, widefield 110° (central angle of view 163°) color SLO enables observation of the entirety of the proliferative membrane and the retinal changes in the superior periphery, in addition to asteroid hyalosis.

89-Year-Old Male



Standard 60° (central angle of view 89°)

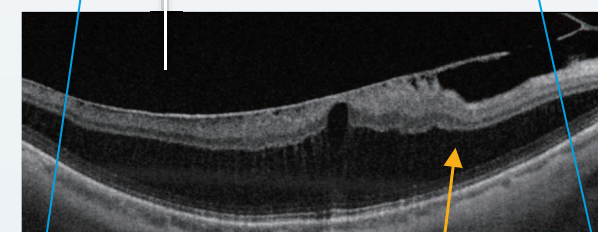
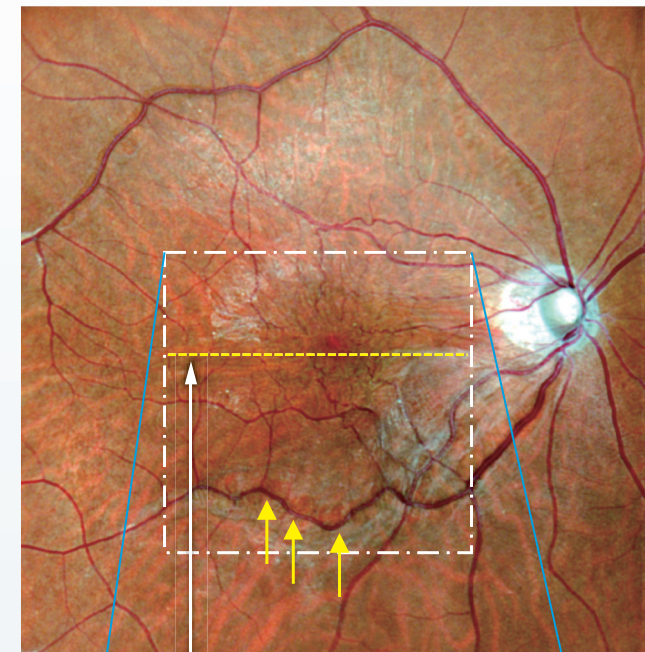


Widefield 110° (central angle of view 163°)

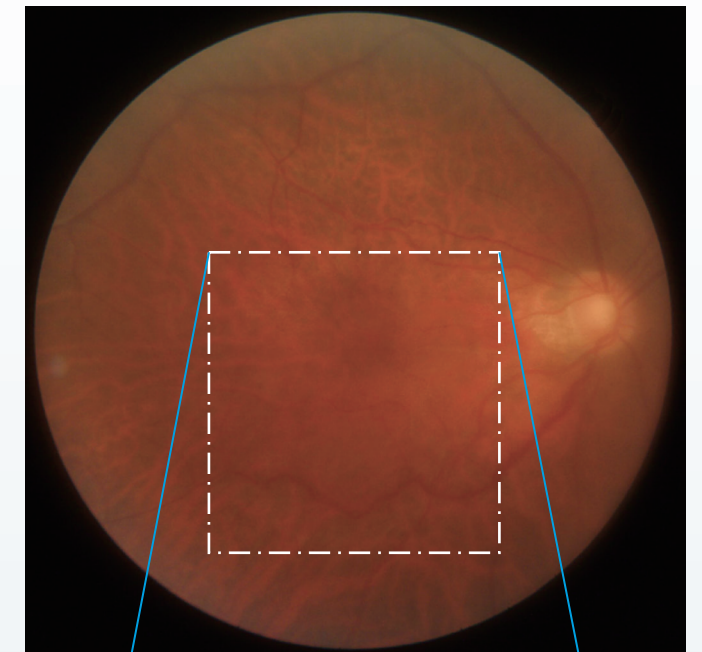
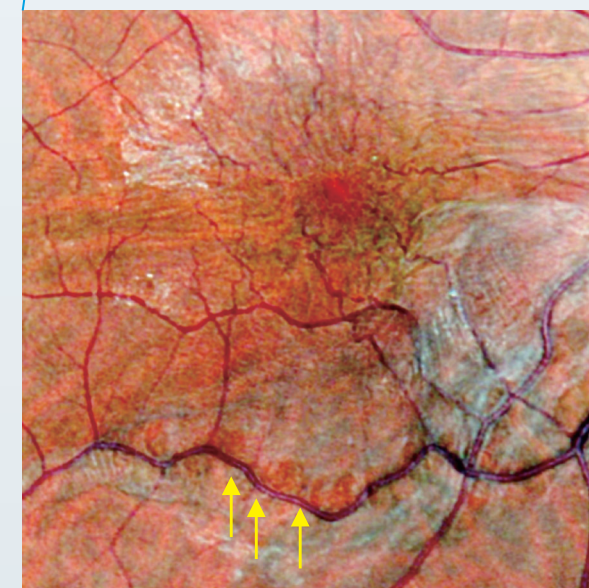
# Vitreomacular Traction Syndrome

Case 36 Findings of retinal folds and retinoschisis caused by strong contraction of an epiretinal membrane (ERM) associated with severe myopia are confirmed. Strong traction due to membrane contraction results in retinal color changes along the blood vessels in the inferior vascular arcades (yellow arrows). With the magnified images below, the difference in observation is clear compared to the fundus camera. This is one of the retinal morphological changes that is first observed with color SLO.


60-Year-Old Male



Retinoschisis is induced due to the significant longitudinal traction.



Fundus camera image



Fundus camera image

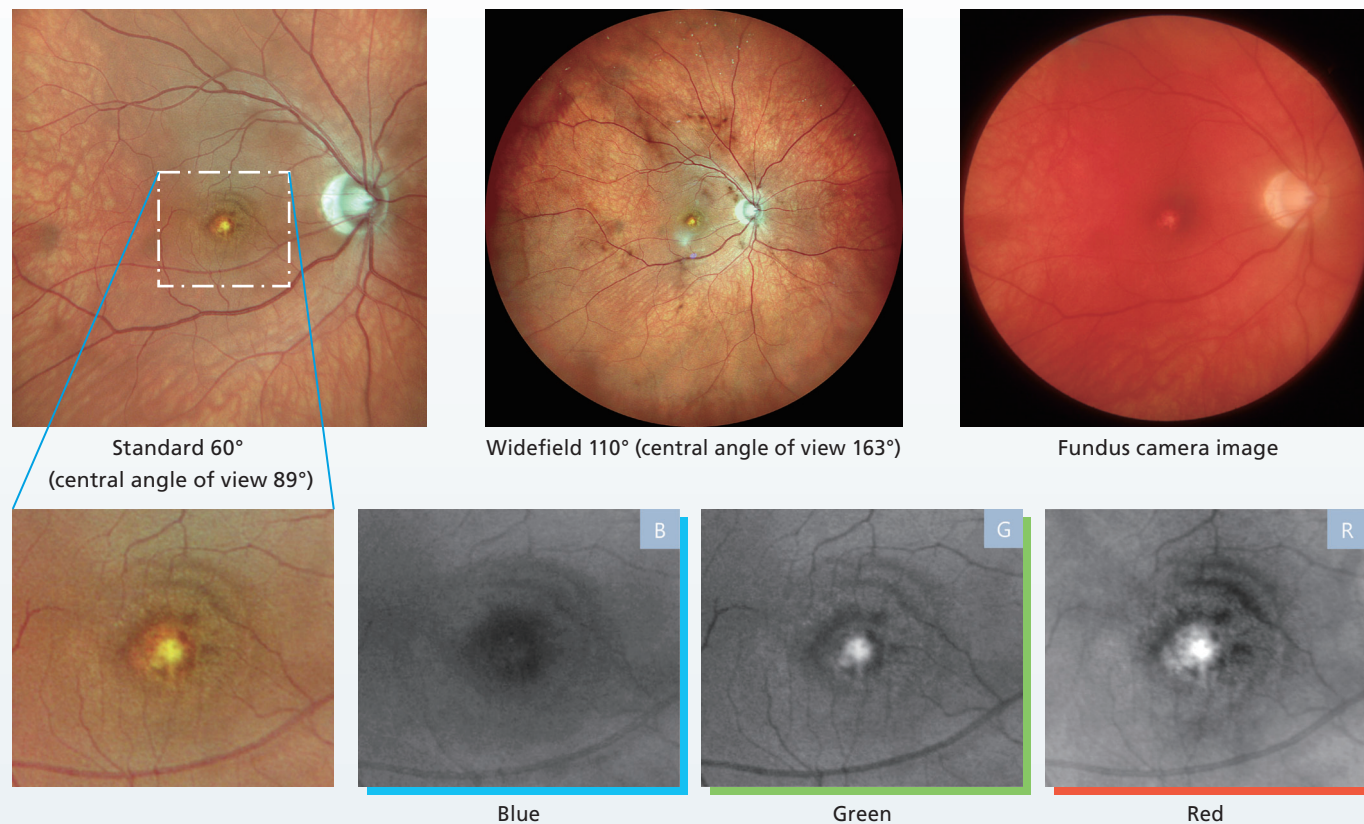


# Vogt-Koyanagi-Harada Disease

## Case 37

42-Years-Old  
Male

An example of Vogt-Koyanagi-Harada disease. Although it is slightly different from the sunset-like color tone observed with the fundus camera, the changes in fundus color and choroidal blood vessels are well depicted with the widefield 110° (central angle of view 163°) color SLO imaging with the Mirante. With standard 60° (central angle of view 89°) color SLO, choroidal neovascularization (CNV) can be observed in the macula. The CNV is clearly visible, indicating low activity at the current stage. Magnified images indicate that lesions that are not depicted with the blue wavelength are best observed with the red wavelength, illustrating how each wavelength reflects the depth information also.

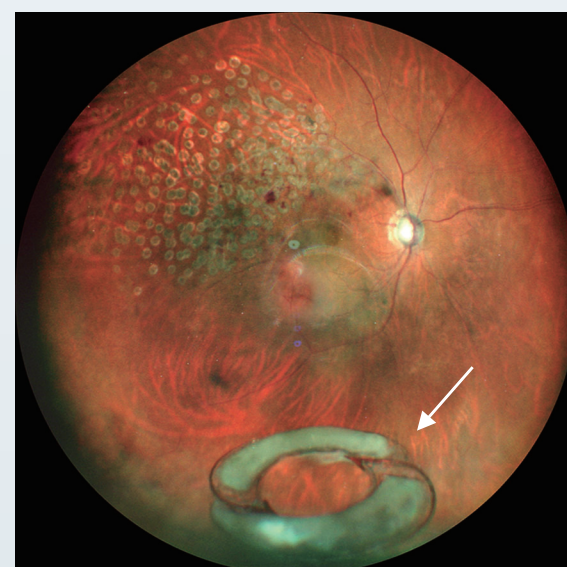


# IOL Dislocation

## Case 38

82-Year-Old  
Male

Widefield color SLO imaging indicates IOL dislocation (white arrow) with the lens and adapter capsule sitting below the vitreous body. The extent of retinal photocoagulation for retinal vein occlusion (RVO) is also visible in this image.

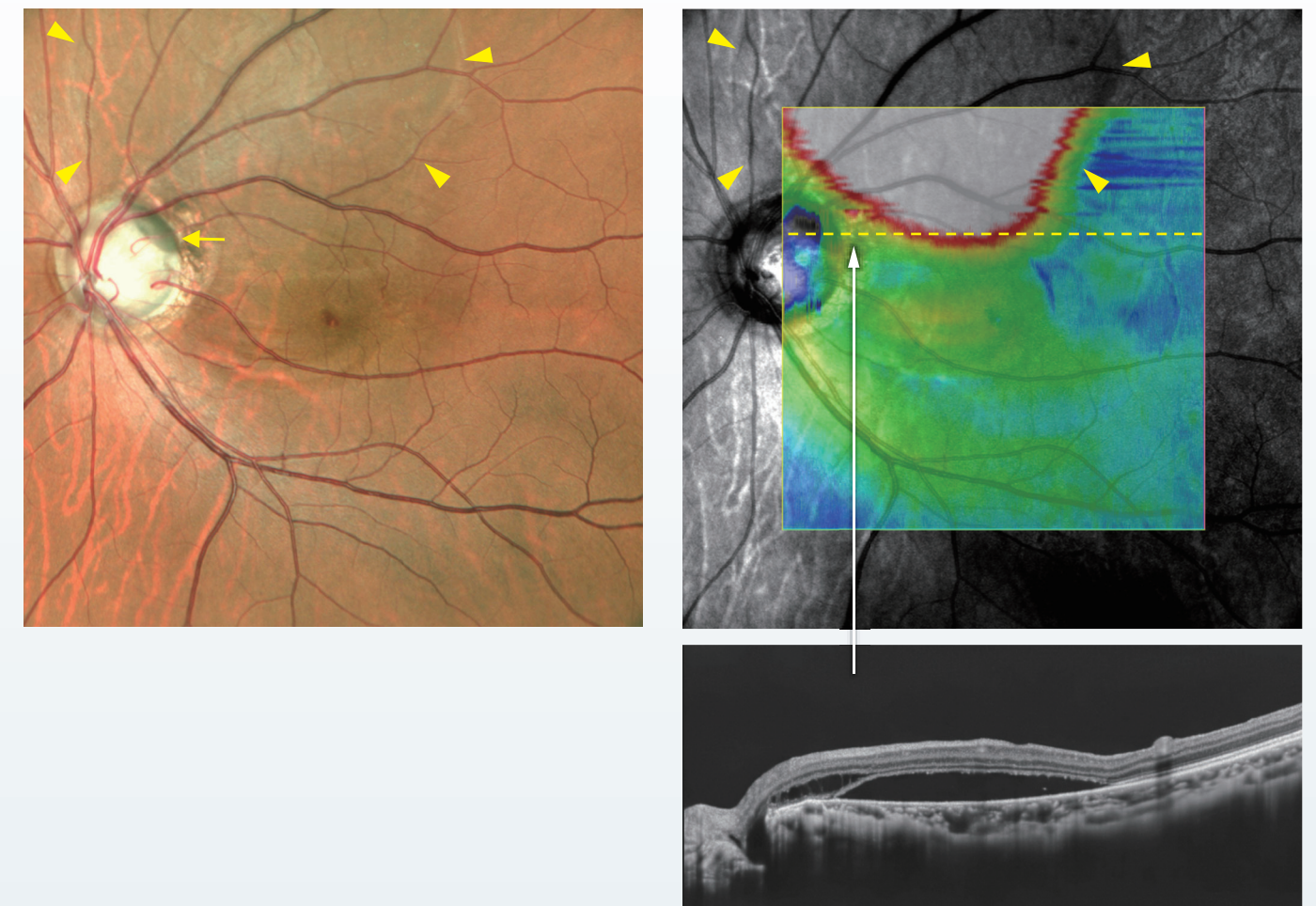

# Pit Macular Syndrome

## Case 39

38-Year-Old  
Male

A pit with a different color tone is observed within the optic disc (yellow arrow). In addition, serous retinal detachment (yellow arrowheads) is present from the macula to the upper vascular arcades centered around the pit.



# Optic Disc Melanocytoma

## Case 40

42-Year-Old  
Male

The uneven pigmentation on the surface of the tumor is easily visible. It is evident that the cytoma is spreading over the macula (blue asterisk).

